

Tracheostomy Emergencies



Laura J. Bontempo, MD, MEd*, Sara L. Manning, MD

KEYWORDS

- Tracheostomy • Airway • Decannulation • Obstruction
- Tracheoinnominate artery fistula • Tracheal stenosis

KEY POINTS

- Replacement of a decannulated tracheostomy fewer than 7 days old should be attempted only under direct visualization.
- A completely obstructed tracheostomy tube must be removed to maintain airway patency.
- All tracheostomy bleeding should be considered a sentinel bleed and the source must be identified, even if the bleeding resolves.
- Chronic and subacute tracheostomy complications can present months to years after placement or decannulation.

INTRODUCTION

More than 110,000 tracheostomies are placed annually in the United States.¹ The overall complication incidence is 40% to 50%. Thankfully, the vast majority of these complications are minor. One percent of tracheostomy patients, however, will suffer a catastrophic tracheostomy-related complication. Of those patients, up to half will die. It is, therefore, incumbent for the emergency provider to be able to recognize the signs and symptoms of tracheostomy-related emergencies and provide initial stabilization and, potentially, life-saving interventions.

Tracheostomy-related complications are generally grouped by their peak incidence of occurrence.^{2,3} Intraoperative complications, including hemorrhage, air embolism, and damage to the trachea, are not within the treatment domain of the emergency physician and will not be discussed here. Intermediate (early postoperative) complications include hemorrhage, tube decannulation, extratracheal air (subcutaneous emphysema, pneumothorax, pneumomediastinum), and infection. Late postoperative complications include hemorrhage, tracheal stenosis, tube decannulation, and fistula formation.^{2,4} The delineation between intermediate and late complications is variable;

Disclosure Statement: The authors have no financial interests to disclose.

Department of Emergency Medicine, University of Maryland School of Medicine, 110 South Paca Street, 6th Floor, Suite 200, Baltimore, MD 21201, USA

* Corresponding author.

E-mail address: lbontempo@som.umaryland.edu

Emerg Med Clin N Am 37 (2019) 109–119

<https://doi.org/10.1016/j.emc.2018.09.010>

0733-8627/19/© 2018 Elsevier Inc. All rights reserved.

emed.theclinics.com

however, the Agency for Healthcare Research and Quality reported that tracheostomies have the fifth-highest 30-day readmission rate for procedures performed during the index stay. Nearly 1 in 4 patients with tracheostomy will require hospital admission within 30 days of having their tracheostomy placed.⁵ More than 90% of catastrophic complications occur more than 1 week after tracheostomy placement.⁶

For the purposes of emergency management, tracheostomy complications are grouped into emergent life-threatening complications and urgent complications. Emergent life-threatening complications include tube decannulation, tube obstruction, and hemorrhage. Urgent subacute complications include tracheoesophageal fistula formation, tracheal stenosis, infection, and tracheocutaneous fistula formation.

The management of both emergent and urgent tracheostomy complications may be further complicated by the underlying condition of the patient who originally necessitated the placement of the tracheostomy. Indications for tracheostomy placement include upper respiratory tract obstruction, prolonged ventilation, copious secretions, severe obstructive sleep apnea, and head/neck surgery.³ Such comorbid conditions must be considered when making management decisions.

ANATOMY

Tracheostomies are placed using a percutaneous dilational approach or open surgical approach. With either approach, the goal is to create an opening into the trachea through the anterior neck where the tracheal mucosa is brought into continuity with the skin.⁷ The complication rate between the 2 techniques is similar.⁸ The indications for performing a tracheostomy are upper airway obstruction, control of secretions, the necessity of long-term ventilation, and the necessity for long-term airway protection.^{9,10}

Using either technique, tracheostomies are generally placed between the second and third tracheal rings.¹¹ Higher incisions increase the risk of laryngeal injury and lower incisions increase the risk of decannulation and vessel injury.⁷

EMERGENT LIFE-THREATENING COMPLICATIONS

Tracheostomy Decannulation

Inadvertent tracheostomy tube decannulation can occur at any time following tracheostomy placement. The reported incidence of tracheostomy displacement varies widely. The literature reports rates between 0.35% and 15%.^{2,12,13} It is the second most frequent life-threatening early pediatric tracheostomy complication,¹⁴ and in the critical care setting, 50% of airway-related deaths were associated with tracheostomy displacement.¹⁵ Many decannulations may be handled by the patient or caregiver without seeking further care, so the incidence may be higher than reported. Decannulations within the first week of placement are most concerning because of the lack of mature stoma formation and a narrower tracheocutaneous tract, which increases the risk of airway loss.¹⁶

Risk factors for accidental tracheostomy decannulation include mental status change, traumatic brain injury, increased secretions, recent tracheostomy change, increased neck thickness, and pediatric age.^{2,14,16} Tracheostomies placed using a percutaneous technique are at higher risk for decannulation than those placed using an open surgical approach.³

When a patient presents to the Emergency Department (ED) with a displaced tracheostomy tube, 2 key pieces of information must be obtained. First, how long ago was the tracheostomy placed, and second, how long before presentation did the tracheostomy become decannulated. The patient may present with the tracheostomy

completely displaced from the stoma or with the tracheostomy partially displaced with the tip present in the soft tissue of the neck. When decannulation occurs, replacement without delay is indicated. Even a mature stoma may significantly narrow over the course of hours, making delayed recannulation more challenging and necessitating the use of a smaller tracheostomy tube during replacement.¹⁷

Replacement of a dislodged tracheostomy within the first week of placement should be attempted only with direct visualization via fiberoptic endoscopy to reduce the risk of creating a false passage into the soft tissue of the neck.^{3,17} If fiberoptic visualization is unavailable or is unsuccessful, then oral intubation may be necessary to secure the airway and ventilate the patient (Fig. 1). For tracheostomies placed more than 7 days before dislodgement, a new tracheostomy tube may be inserted through the stoma with placement then confirmed by fiberoptic visualization.

Regardless of the age of the tracheostomy, if resistance is met, a smaller tracheostomy tube should be selected and insertion reattempted. If recannulating is unsuccessful, bag-valve ventilation and oral intubation may be necessary if the patient fails to oxygenate or ventilate.^{3,17,18} If a replacement tracheostomy tube is not readily available, an analogous size endotracheal tube may be inserted through the stoma until a tracheostomy tube can be obtained.¹⁸

Following recannulation, low-volume, gentle bag-valve ventilation can be used to assist ventilation.¹⁵ If subcutaneous emphysema develops, tracheostomy placement must be evaluated through direct visualization due to possible false passage with placement of the tracheostomy tube into the paratracheal soft tissue of the

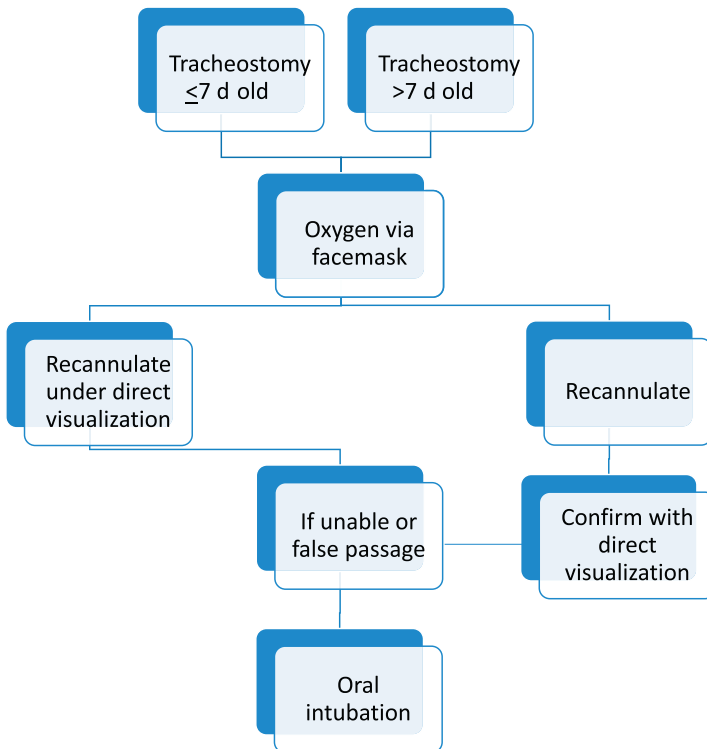


Fig. 1. Tracheostomy decannulation algorithm.

neck.^{19,20} If proper placement is confirmed, the trachea must be subsequently evaluated for injury. Once recannulated, continuous capnometry is used to monitor ventilation.

Tracheostomy Obstruction

Obstruction of the lumen of a tracheostomy tube can result from dried secretions, mucous plugs, clotted blood, partial tube displacement, impingement by the posterior tracheal wall, granulation tissue buildup, or displacement of the tracheostomy into a false lumen. It can occur at any time and is the leading cause of tracheostomy-related death in pediatric patients.⁶ Risk factors for obstruction include small tracheostomy tube size, single cannula tracheostomy tube, and poor tracheostomy care.^{3,18}

Management of tracheostomy obstruction requires a stepwise approach (Fig. 2). An initial simple step is to remove anything potentially obstructing the external end of the tracheostomy lumen, such as a speaking valve, obturator, decannulation cap, bandages, or humidifying devices.¹⁵ Removal of the inner cannula of a double-cannula tracheostomy and suctioning of single or double-cannula tracheostomies are the next steps when obstruction is suspected and will relieve most obstructions.^{3,18}

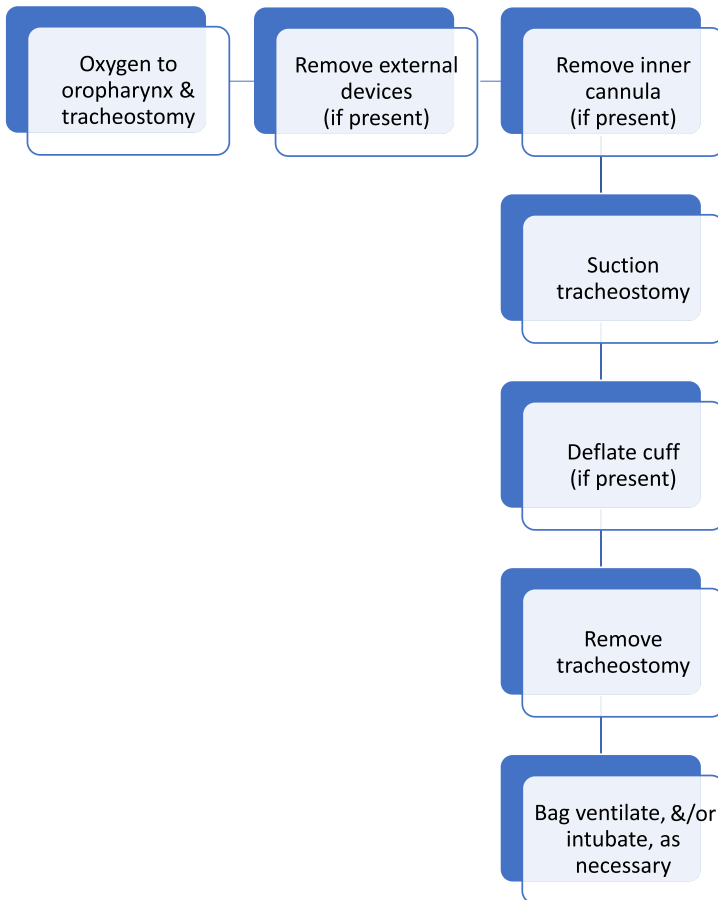


Fig. 2. Tracheostomy occlusion algorithm.

If a suction catheter can be passed through the entire length of the tracheostomy into the native trachea, a complete obstruction is not present. The patient's ventilation can be assisted with positive pressure as necessary to improve ventilation and oxygenation. If a suction catheter cannot be passed, a complete obstruction of the tracheostomy tube is present. Stiff instruments, such as gum-elastic bougies and tube changers, are not recommended to assess patency because they do not allow for removal of secretions and can create a false passage if the tracheostomy is obstructed due to partial or complete displacement.¹⁵

If the tracheostomy tube is cuffed, the cuff must be deflated to allow for airflow around the tracheostomy tube because flow through the tracheostomy tube lumen is occluded. If the obstruction is relieved by other means or if a new tracheostomy is placed, the balloon will need to be inflated to provide effective positive pressure ventilation.

When, despite these measures, a patient continues to be distressed from airway obstruction, the tracheostomy tube must be removed. Although removing the artificial airway may seem counterintuitive in a distressed patient, a nonfunctioning tracheostomy offers no benefit to the patient. Following removal, ensure that the patient is receiving high-flow oxygen via both face and tracheostomy stoma. If the obstruction is relieved and the patient is ventilating, as monitored by capnometry, it is not necessary to emergently reinsert an airway.¹⁵

Following tracheostomy removal, if bag-valve-mask ventilatory assistance is used, it is necessary to remember that the patient has 2 airway openings (tracheostomy and oro-nasopharynx). If the patient is ventilated via the mouth, the tracheal stoma must be occluded with gauze (**Fig. 3**). If the patient is ventilated via the tracheal stoma, the oral and nasal pharynx must be occluded. To generate airway positive pressure when ventilating, a pediatric face mask or laryngeal-mask airway can be placed over the stoma (**Fig. 4**).¹⁵ If effective oxygenation and ventilation is not achieved with bag-valve maneuvers, intubation should be attempted. If intubating by the oropharynx, the endotracheal tube must be advanced beyond the stoma to generate positive pressure in the lower airway after the balloon is inflated. If the tracheostomy is more than a week old or if oral intubation is anticipated to be difficult, intubation of the stoma can be attempted. A smaller tracheostomy tube or endotracheal tube can be placed

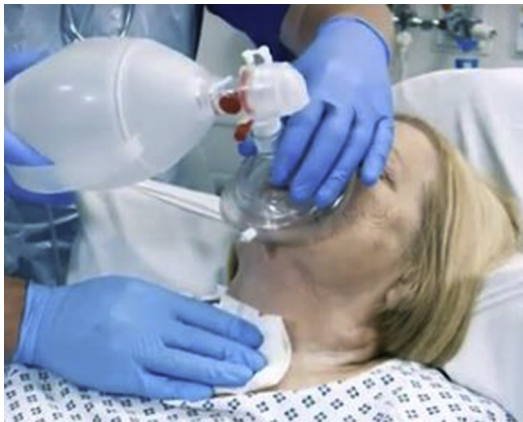

Fig. 3. Occluding the ostomy to facilitate oro-nasopharyngeal bag-valve-mask ventilation. (Courtesy of National Tracheostomy Safety Project; with permission.)

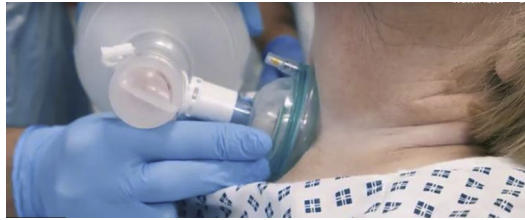

Fig. 4. Ventilating via tracheostomy stoma with a pediatric bag-valve-mask. (Courtesy of National Tracheostomy Safety Project; with permission.)

directly into the stoma. Guided placement using a fiberoptic scope, Bougie, or tube exchange catheter is preferred.¹⁵

When the obstruction is partially or completely relieved after any step in the algorithm, the patient's ventilation should be monitored with continuous capnometry and pulse-oximetry and assisted with positive pressure ventilation as the clinical situation necessitates.

Hemorrhage

Tracheostomy bleeding complicates up to 5% of tracheostomies and ranges from minor to life-threatening. Bleeding within the first 48 hours after placement is usually related to operative issues, including inadvertent vein puncture, suctioning, and infection.²¹ Beyond 48 hours, the most critical and feared hemorrhagic complication is the development of a tracheo-innominate artery (TIAF) fistula. This is a direct connection between the native trachea and the innominate artery branch of the aorta. The incidence of TIAF is approximately 0.7% of patients with tracheostomy and the mortality is more than 90%.^{2,21,22} Nearly 75% of TIAF bleeds will occur within 3 weeks following tracheostomy placement but may occur at any time.^{21–23}

Up to 50% of TIAF bleeds will have a sentinel event, such as tracheostomy site bleeding, hemoptysis, or blood seen with tracheal suctioning.²¹ Therefore, any tracheostomy-related hemorrhage, especially occurring within 3 weeks of placement, must be considered a TIAF bleed until proven otherwise. Diagnostic options include bronchoscopy, computed tomography or traditional angiography, or local exploration.^{18,24}

The innominate artery crosses anterior to the trachea, typically at the level of the ninth tracheal ring; however, there is significant anatomic variation and the innominate artery may cross the trachea superior enough to be anterior to a tracheostomy tube. Pressure on the anterior tracheal wall results in mucosal ischemia and can lead to fistula formation with the posterior wall of the innominate artery. Risk factors include a cuffed tracheostomy tube, low tracheostomy placement, high cuff pressure, high-riding innominate artery, excessive neck movement, and tracheostomy infection.^{23,25}

If catastrophic tracheostomy bleeding occurs, a TIAF should be assumed and immediate resuscitative measures undertaken while attempts to temporize the bleeding and facilitate operative repair are made (Fig. 5). Initial intervention attempts include external compression of the innominate artery by applying pressure posteriorly at the sternal notch, and internal compression through overinflation of the tracheostomy balloon with up to 50 mL of air. These interventions are reported to be successful as a temporizing measure 85% of the time.²³ If a cuffed tracheostomy tube is not present or overinflation has failed to control the bleeding, the tracheostomy tube can be removed and the airway secured via oral or stomal intubation with an endotracheal

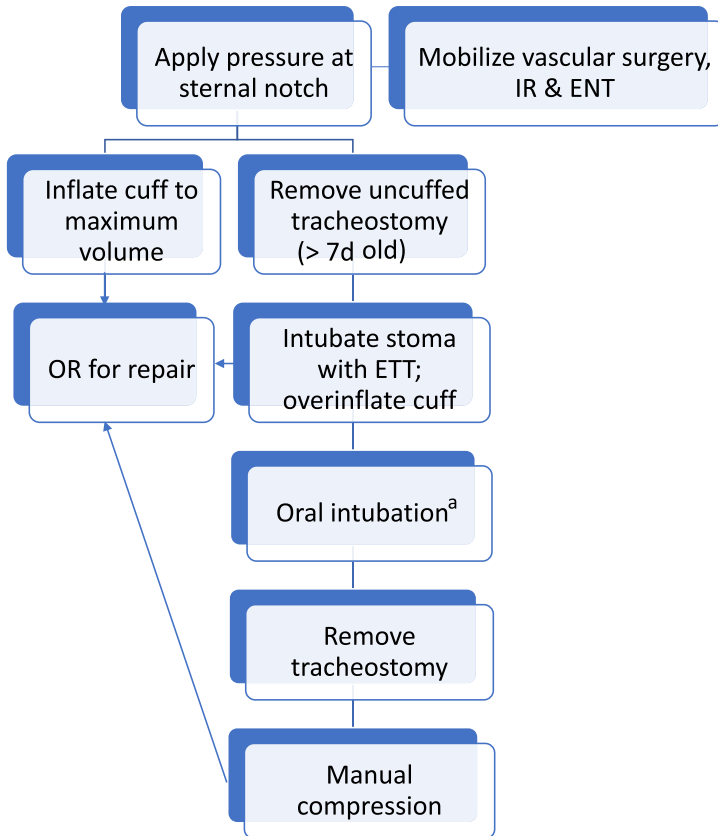


Fig. 5. Large-volume tracheostomy hemorrhage algorithm. ENT, otolaryngology; ETT, endotracheal tube; IR, interventional radiology; OR, operating room. ^a Advance balloon distal to tracheostomy then inflate; may require concurrent tracheostomy removal.

tube whose cuff is then overinflated with up to 50 mL of air. If this also proves to be unsuccessful, an oral endotracheal tube can be advanced beyond the stoma to secure the airway with the addition of a finger inserted into the tracheostomy for digital compression of the innominate artery anteriorly against the manubrium.²⁶ Digital compression must be maintained until definitive repair is undertaken.

These maneuvers are all performed in an attempt to decrease the amount of blood loss while getting the patient to the operating room or interventional radiology suite for definitive management.²¹

URGENT COMPLICATIONS

Tracheoesophageal Fistula

A tracheoesophageal fistula (TEF) is a communication between the posterior wall of the trachea and the anterior wall of the esophagus. Prolonged pressure on the posterior membranous wall of the trachea from a tracheostomy balloon results in ischemic necrosis, tissue breakdown, and subsequent fistula formation.²⁷ Risk factors include high airway pressures, prolonged presence of a cuffed tracheostomy tube, high cuff pressures, excessive tracheostomy movement, steroid use, type 1 diabetes mellitus,

chronic hypoxia, poor nutritional status, hypotension, anemia, sepsis, the presence of a nasogastric tube, and gastro-esophageal reflux disease (GERD).^{27,28}

TEFs may manifest as persistent tracheal air leaks, abdominal distention (from air entering the digestive tract), pulmonary aspiration injury, cough with swallowing, copious bronchopulmonary secretions, and respiratory distress. In patients with tracheostomy, the TEF is generally located 1 to 2 cm distal to the tracheal stoma at the level of the balloon and can be large, measuring 4 to 5 cm. Diagnosis is made by bronchoscopy or, if not available, esophagram.

Emergency management includes stopping contamination of the airway through tracheal suctioning, discontinuation of oral feeding, and elevation of the patient's head to 45°. If a gastric tube is present, it should be used to drain the contents of the stomach. However, if a nasogastric tube is in place, it should be removed to prevent pressure necrosis and worsening of the fistula.²⁷ Additionally, any suppurative complications, such as pneumonia, should be treated.

Long-term treatment consists of conservative management with adjustment of the tracheostomy balloon to a more distal position and nutrition via jejunostomy tube, minimally invasive treatment with tracheal and esophageal stents, or surgery.²⁷

Tracheal Stenosis

Tracheal stenosis is common after prolonged intubation or tracheostomy, with most patients experiencing some degree of tracheal narrowing. However, only 3% to 12% of cases require any intervention and very few of those patients experience critical stenosis requiring urgent intervention.^{2,29,30} Stenosis occurs secondary to granulation tissue and fibrosis of peristomal and tracheal tissues. After granulation tissue forms, it eventually becomes covered with epithelial tissue.³

Trauma to the trachea either from injury during the procedure itself or ischemia from balloon over inflation leads to tracheal inflammation and ulceration. Other risk factors include surgical site infection, GERD, obesity, and hypotension.^{29,30} Tracheal stenosis frequently occurs at the site of the stoma, the level of the tracheostomy tube tip, the site of the balloon, or in a suprastomal position. Stenosis will not cause symptoms until the diameter of the tracheal lumen is reduced by more than 50%.^{29,30} Early symptoms include difficulty clearing secretions, cough, and exertional dyspnea. Dyspnea at rest and stridor are associated with a tracheal diameter of ≤ 5 mm.²⁹ Tracheal stenosis can occur while a patient is still mechanically ventilated or years after decannulation, but most will present within 2 months of decannulation.³

Stenosis can make tube exchanges difficult due to narrowing of the space and bleeding risk. Early stenosis with exposed granulation tissue without overlying epithelium can bleed easily with minor trauma.²⁹ Stenosis can be treated with dilation, excision with end-to-end anastomosis, or laser excision of granulation or fibrous tissues.^{3,30}

Infection

Tracheostomy is considered a "clean-contaminated" procedure due to the entrance of the upper aerodigestive tract. Bacterial colonization of the skin and aerodigestive tract combined with the rich environment of blood and secretions at the surgical site place patients at risk of surgical site infection. Strict wound care with frequent dressing changes is the cornerstone of preventing infection after tracheostomy. Common early infections include cellulitis and tracheitis.² These infections frequently occur early in the postoperative course and are more commonly observed after open versus percutaneous tracheostomy.³ Most early infections are minor, but severe infections, including mediastinitis and necrotizing fasciitis, are possible.³¹ Delayed presentations

of serious infections have been observed, most notably osteomyelitis and septic arthritis of the sternoclavicular joint.³²

The presence of a tracheostomy tube, especially a cuffed tube, disrupts swallowing, thus increasing the risk of aspiration. An overinflated tube cuff can compress the esophagus, leading to aspiration. This aspiration is often asymptomatic or silent and therefore unrecognized by patients and caregivers.²⁹ Aspiration of infected secretions can result in pneumonia or lung abscesses. These infections are most commonly attributed to *Staphylococcus aureus*, *Pseudomonas*, and mixed flora.²

Pneumonias and severe skin and soft tissue infections should be treated aggressively. Despite the frequency of infectious complications, the role of perioperative antibiotics in tracheostomy remains controversial.^{2,31}

Cutaneous Fistula

After decannulation, most stomas close in approximately 6 weeks. Persistent epithelialization of the stoma track can result in fistula formation. If the stoma persists after 3 to 6 months, a tracheocutaneous fistula is diagnosed.³ Persistent tracheocutaneous fistulas can lead to skin irritation and infection due to draining secretions, weak cough, and aspiration leading to recurrent pneumonias, poor phonation, poor cosmesis, and submersion intolerance.³³ The most notable risk factor is prolonged tracheostomy tube placement with one small series noting tracheostomy placement for at least a year in all observed cases.² Other risk factors include steroid use, advanced age, and malnutrition.³ Management options include tract cauterization or excision with healing by secondary intention or surgical closure.^{3,33}

SUMMARY

With more than 110,000 tracheostomies being placed annually in the United States, the emergency provider must be prepared to deal with both catastrophic and urgent tracheostomy-related emergencies. Life-threatening complications, including accidental decannulation, obstruction, and hemorrhage, are rare but require immediate action. Having a predetermined, stepwise approach to these complications will help guide management when such patients arrive in the ED.

Subacute complications, such as tracheoesophageal fistula formation, tracheal stenosis, infection, and cutaneous fistula formation, may occur at any time, ranging from the postoperative period to years after a tracheostomy was placed or even following decannulation.

The emergency provider must maintain a high index of suspicion for a tracheostomy-related complication when a patient with a present or prior tracheostomy presents with fever, dyspnea, or hemoptysis.

REFERENCES

1. Shah RK, Lander L, Berry JG, et al. Tracheotomy outcomes and complications: a national perspective. *Laryngoscope* 2012;122(1):25–9.
2. Goldenberg D, Ari EG, Golz A, et al. Tracheotomy complications: a retrospective study of 1130 cases. *Otolaryngol Head Neck Surg* 2000;123(3):495–500.
3. Fernandez-Bussy S, Mahajan B, Folch E, et al. Tracheostomy tube placement: early and late complications. *J Bronchology Interv Pulmonol* 2015;22(4):357–64.
4. Cheung NH, Napolitano LM. Tracheostomy: epidemiology, indications, timing, technique, and outcomes. *Respir Care* 2014;59(6):895–919.
5. Weiss AJ, Elixhauser A, Steiner C. Readmission to US hospitals by procedure, 2010: statistical brief #154. Healthcare cost and utilization Project (HCUP)

- statistical briefs. Rockville (MD): Agency for Healthcare Research and Quality (US); 2006–2013. p. 1–17.
6. Das P, Zhu H, Shah RK, et al. Tracheotomy-related catastrophic events: results of a national survey. *Laryngoscope* 2012;122(1):30–7.
 7. McWhorter AJ. Tracheotomy: timing and techniques. *Curr Opin Otolaryngol Head Neck Surg* 2003;11(6):473–9.
 8. Oliver ER, Gist A, Gillespie MB. Percutaneous versus surgical tracheotomy: an updated meta-analysis. *Laryngoscope* 2007;117:1570–5.
 9. Heffner JE, Miller S, Sahn SA. Tracheostomy in the intensive care unit: part 1: indications, technique, management. *Chest* 1986;90:269–74.
 10. Yaghoobi S, Kayalha H, Ghafouri R, et al. Comparison of complications in percutaneous dilatational tracheostomy versus surgical tracheostomy. *Glob J Health Sci* 2014;6(4):221–5.
 11. Cipriano A, Mao ML, Hon HH, et al. An overview of complications associated with open and percutaneous tracheostomy procedures. *Int J Crit Illn Inj Sci* 2015;5(3): 179–88.
 12. Kapadia FN, Tekawade PC, Nath SS, et al. A prolonged observational study of tracheal tube displacements: benchmarking an incidence <0.5–1% in a medical-surgical adult intensive care unit. *Indian J Crit Care Med* 2014;18(5): 273–7.
 13. Friedman Y, Fildes J, Mizock B, et al. Comparison of percutaneous and surgical tracheostomies. *Chest* 1996;110(2):480–5.
 14. Kremer B, Botos-Kremer AI, Eckel HE, et al. Indications, complications, and surgical techniques for pediatric tracheostomies—an update. *J Pediatr Surg* 2002; 37(11):1556–62.
 15. McGrath B, Bates L, Atkinson D, et al, National Tracheostomy Safety Project. Multidisciplinary guidelines for the management of tracheostomy and laryngectomy airway emergencies. *Anaesthesia* 2012;67(9):1025–41.
 16. Lerner AD, Yarmus L. Percutaneous dilatational tracheostomy. *Clin Chest Med* 2018;39:211–2.
 17. O'Connor HH, White AC. Tracheostomy decannulation. *Respir Care* 2010;55(8): 1076–81.
 18. Mitchell RB, Hussey HM, Setzen G, et al. Clinical consensus statement: tracheostomy care. *Otolaryngol Head Neck Surg* 2013;148(1):6–20.
 19. Lyons MJ, Cooke J, Cochrane LA, et al. Safe reliable atraumatic replacement of misplaced paediatric tracheostomy tubes. *Int J Pediatr Otorhinolaryngol* 2007; 71(11):1743–6.
 20. Klancir T, Adam VN, Mršić V, et al. Bilateral pneumothorax as a complication of percutaneous tracheostomy: case report. *Acta Clin Croat* 2016;55(Suppl 1): 98–102.
 21. Bradley PJ. Bleeding around a tracheostomy wound: what to consider and what to do? *J Laryngol Otol* 2009;123(9):952–6.
 22. Scalise P, Prunk SR, Healy D, et al. The incidence of tracheoarterial fistula in patients with chronic tracheostomy tubes: a retrospective study of 544 patients in a long-term care facility. *Chest* 2005;128(6):3906–9.
 23. Wang RC, Perlman PW, Parnes SM. Near-fatal complications of tracheotomy infections and their prevention. *Head Neck* 1989;11(6):528–33.
 24. Reger B, Neu R, Hofmann HS, et al. High mortality in patients with tracheoarterial fistulas: clinical experience and treatment recommendations. *Interact Cardiovasc Thorac Surg* 2018;26(1):12–7.

25. Jones JW, Reynolds M, Hewitt RL, et al. Tracheo-innominate artery erosion: successful surgical management of a devastating complication. *Ann Surg* 1976; 184(2):194–204.
26. Allan JS, Wright CD. Tracheoinnominate fistula: diagnosis and management. *Chest Surg Clin N Am* 2003;13:331–41.
27. Paraschiv M. Tracheoesophageal fistula—a complication of prolonged tracheal intubation. *J Med Life* 2014;7(4):516–21.
28. Menezes RG, Pant S, Prasad SC, et al. An autopsy case of iatrogenic tracheoesophageal fistula secondary to tracheostomy. *Am J Forensic Med Pathol* 2014; 35(2):77–9.
29. Epstein SK. Late complications of tracheostomy. *Respir Care* 2005;50:542–9.
30. Zias N, Chroneou A, Tappa MK, et al. Post tracheostomy and post intubation tracheal stenosis: report of 31 cases and review of the literature. *BMC Pulm Med* 2008;8:18.
31. Sittitrai P, Siriwittayakorn C. Perioperative antibiotic prophylaxis in open tracheostomy: a preliminary randomized controlled trial. *Int J Surg* 2018;54(Pt A):170–5.
32. Sharif KF, Baik FM, Jategaonkar AA, et al. Septic arthritis of the sternoclavicular joint: a unique late complication after tracheostomy. *Am J Otolaryngol* 2018. <https://doi.org/10.1016/j.amjoto.2018.05.005>.
33. Wine TM, Simons JP, Mehta DK. Comparison of 2 techniques of tracheocutaneous fistula closure. *JAMA Otolaryngol Head Neck Surg* 2014;140(3):237–42.