

CLINICAL PRACTICE

Caren G. Solomon, M.D., M.P.H., *Editor*

Pregnancy Complicated by Venous Thrombosis

Ian A. Greer, M.D.

This Journal feature begins with a case vignette highlighting a common clinical problem. Evidence supporting various strategies is then presented, followed by a review of formal guidelines, when they exist. The article ends with the author's clinical recommendations.

A 37-year-old primigravid woman presents at 12 weeks of gestation with a painful, swollen left leg, breathlessness, and lower abdominal pain. She has had hyperemesis for several weeks. She has no personal history of venous thrombosis, but she reports a family history of thrombosis in both her mother and her maternal aunt. On examination, she has a body-mass index (BMI, the weight in kilograms divided by the square of the height in meters) of 36, and the entire leg is dusky and swollen. No abnormalities are detected on pulmonary examination, and the oxygen saturation is normal. How should her case be evaluated and treated?

THE CLINICAL PROBLEM

VENOUS THROMBOEMBOLISM IS A LEADING CAUSE OF MATERNAL MORTALITY and morbidity in the developed world. The risk of these consequences may be avoided or reduced with improved treatment and prophylaxis.¹⁻³ As compared with deep-vein thrombosis in nonpregnant persons, deep-vein thrombosis in pregnant women occurs more frequently in the left leg (85%, vs. 55% in the left leg among nonpregnant persons) and is more often proximal (72% in the iliofemoral veins, vs. 9% in the iliofemoral veins among nonpregnant persons),⁴ with a greater risk of embolic complications and the post-thrombotic syndrome.²

Although the absolute incidence of venous thromboembolism in pregnancy is low (1 or 2 cases per 1000 pregnancies),³ this risk is approximately five times as high as the risk among women who are not pregnant.⁵ These risks reflect the venous stasis and procoagulant changes in coagulation and fibrinolysis, which are considered to be part of physiologic preparation for the hemostatic challenge of delivery. Thrombotic events occur throughout pregnancy, with more than half occurring before 20 weeks of gestation.^{6,7} The risk increases further in the puerperium (the 6-week period after delivery), probably owing to endothelial damage to the pelvic vessels that occurs during delivery. Recent data indicate that an increased relative risk (but low absolute risk) persists until 12 weeks after delivery.⁸ However, approximately 80% of postpartum thromboembolic events occur in the first 3 weeks after delivery.⁹

Venous thrombosis is a “multi-hit” disease. One of the strongest risk factors is a previous pregnancy-related venous thrombosis (the risk of recurrence is approximately 6 to 9% in a subsequent pregnancy),¹⁰ but multiple risk factors often coexist in women in whom venous thromboembolism develops in pregnancy.

From the Faculty of Medical and Human Sciences, University of Manchester, Manchester, United Kingdom. Address reprint requests to Dr. Greer at the Faculty of Medical and Human Sciences, University of Manchester, 46 Grafton St., Manchester M13 9NT, United Kingdom, or at ian.greer@manchester.ac.uk.

N Engl J Med 2015;373:540-7.
DOI: 10.1056/NEJMc1407434

Copyright © 2015 Massachusetts Medical Society.



An audio version
of this article
is available at
NEJM.org

KEY CLINICAL POINTS

VENOUS THROMBOSIS IN PREGNANCY

- Venous thromboembolism is a leading cause of maternal mortality and morbidity in the developed world.
- The risk of deep-vein thrombosis is increased in pregnancy and even more so in the puerperium.
- Gestational deep-vein thrombosis, as compared with deep-vein thrombosis that occurs in nonpregnant persons, usually occurs in the left leg, and it is proximal rather than distal, with an associated increased risk of embolic complications.
- Compression duplex ultrasonography is indicated in cases of suspected deep-vein thrombosis; if pulmonary imaging is required, ventilation–perfusion lung scanning is usually the preferred initial test for evaluation of pulmonary embolism.
- Low-molecular-weight heparins are generally preferred over unfractionated heparin for treatment of venous thromboembolism in pregnancy, given their better safety profile; they are generally continued for a minimum of 3 months and until 6 weeks post partum.
- Coumarin anticoagulants are contraindicated in pregnancy but can be used in women, including breast-feeding mothers, after delivery.

Recognized risk factors in pregnancy include hyperemesis (owing to associated dehydration and immobility), a high BMI, immobility,¹¹⁻¹³ and thrombophilias (including homozygous factor V Leiden).¹⁰ Postpartum factors associated with an increased risk of venous thrombosis include having undergone a cesarean delivery, especially if it was performed urgently during labor or was associated with other factors such as postpartum hemorrhage, preeclampsia with fetal growth restriction, thrombophilia, and postpartum infection.¹⁰ A detailed discussion of the prevention of thrombosis is beyond the scope of this article, but prophylaxis is discussed elsewhere.¹⁰

STRATEGIES AND EVIDENCE

Limited data are available from randomized trials involving pregnant women to guide the prevention, diagnosis, and treatment of venous thrombosis in pregnancy. Evidence to guide decision making is derived largely from trials involving nonpregnant persons and from observational studies.

DIAGNOSIS

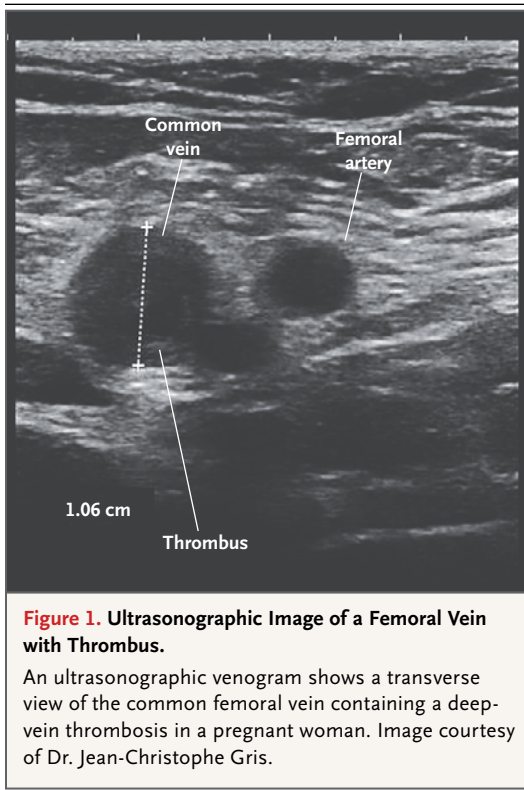
The clinical diagnosis of venous thrombosis is unreliable in pregnancy. Suggestive symptoms and signs, such as leg swelling and dyspnea, may be difficult to differentiate from the physiologic changes of pregnancy. Extension of proximal thrombosis into the pelvic veins or venous distention through the collateral circulation may cause lower abdominal pain, but this symptom is also nonspecific. A high degree of clinical awareness is required for diagnosis. Although less than

10% of clinically suspected thromboembolic events are confirmed,¹⁴⁻¹⁶ objective testing should be performed promptly to minimize the risk of pulmonary embolism.

Suspected deep-vein thrombosis is best assessed by means of compression duplex ultrasonographic examination, including examination of the iliofemoral region (Fig. 1).^{17,18} A prospective study of single compression ultrasonographic examination involving 226 pregnant and postpartum women concluded that this test can safely rule out the diagnosis of deep-vein thrombosis¹⁸; among women with negative findings on examination, only 1.1% (95% confidence interval [CI], 0.3 to 4.0) had a confirmed event on follow-up. In a prospective cohort study involving more than 200 pregnant women with suspected deep-vein thrombosis, serial compression duplex ultrasonography had a negative predictive value of 99.5% (95% CI, 96.9 to 100).¹⁹ In women with a negative result on ultrasonography in whom clinical suspicion of deep-vein thrombosis is high, it may be prudent to repeat the test after 3 to 7 days. It appears to be safe to withhold anticoagulation pending the results of the repeat test.¹⁹

In cases in which ilio caval venous thrombosis is suspected but ultrasonography cannot detect a thrombus, magnetic resonance or conventional x-ray venography may be considered.^{17,20} However, in practice, the majority of patients with ilio caval venous thrombosis have extensive thrombus that is amenable to diagnosis on the basis of ultrasonographic findings.

Chest radiographic findings are normal in the majority of cases of pulmonary embolism, but they can show pulmonary features that point to



an alternative diagnosis or nonspecific features of pulmonary embolism such as atelectasis or regional oligemia.²¹ Electrocardiography may also show tachycardia and nonspecific features of right ventricular strain that suggest pulmonary embolism²⁰ or provide support for alternative diagnoses such as myocardial ischemia. Reduced arterial partial pressure of oxygen or oxygen saturation is uncommon; in a study that included pregnant and postpartum women with pulmonary embolism, fewer than 3% had an oxygen saturation below 90%.²⁰

Since deep-vein thrombosis is often present in patients with pulmonary embolism, ultrasonographic venography is useful in patients who have possible symptoms or signs of deep-vein thrombosis. If deep-vein thrombosis is detected, further radiologic studies do not have to be performed to confirm a pulmonary embolism.²¹ However, a negative result on ultrasonography cannot rule out pulmonary embolism.^{14,20}

In women with normal findings on chest radiography, ventilation–perfusion lung scanning is often recommended, since it has a high negative predictive value, owing to the low prevalence

of coexisting pulmonary problems that can result in indeterminate or false positive test results. Moreover, the ventilation component can often be omitted, thereby minimizing the dose of radiation to the fetus.

Whereas computed tomographic (CT) pulmonary angiography (CTPA), with its high sensitivity and specificity, is usually the first-line test to detect pulmonary embolism in nonpregnant patients, it is used less often in pregnant women. However, it may be valuable in women with abnormal findings on chest radiography or indeterminate findings on ventilation–perfusion scanning. A study comparing ventilation–perfusion and low-dose perfusion scanning with CTPA for the diagnosis of pulmonary embolism in pregnancy showed similar negative predictive values of 100% and 99%, respectively, and similar low rates of uninformative imaging (i.e., poor image quality on CTPA or indeterminate results on ventilation–perfusion scanning).^{15,21,22} CT scanning may also identify an alternative diagnosis such as aortic dissection. However, the maternal radiation dose to the breast tissue with CT scanning (up to 20 mGy, depending on breast size and radiologic technique) may be 20 to 100 times as high as the radiation dose with ventilation–perfusion scanning. Estimates based on modeling have aroused concern that exposure to 10 mGy of radiation may be associated with a small increase in the risk of breast cancer^{20,23,24}; however, the use of bismuth breast shields reduces radiation exposure by up to 40%.²⁵ More information on other imaging techniques such as magnetic resonance pulmonary angiography is required to better understand their usefulness in detecting pulmonary embolism in pregnancy.²⁶

Some clinicians (and patients) are reluctant to pursue objective testing for venous thromboembolism because of concern regarding fetal radiation exposure, but this concern is not well founded, especially if there is a potentially fatal condition in the mother.²⁷ The fetal radiation dose from chest radiography at any gestational age is negligible (<0.1 mGy).²⁸ The estimated fetal radiation exposure from CTPA (0.1 mGy) is similar to the estimated fetal radiation exposure from ventilation–perfusion scanning^{29,30} (0.5 mGy); these exposures are well below the thresholds associated with teratogenesis. Estimates from modeling have suggested that any potential increase in the risk

of fatal childhood cancer associated with this radiation is very small (0.006% per mGy of in utero exposure).^{20,30}

Despite the usefulness of D-dimer measurements in ruling out venous thromboembolism in nonpregnant persons, these measurements are not recommended for evaluation of venous thromboembolism in pregnant women.²⁰ The D-dimer levels increase progressively with advancing gestation such that by term and the postpartum period, measurements are “abnormal” in most uncomplicated pregnancies.³¹ Levels also increase with complications of pregnancy such as preeclampsia.⁴ False negative results have also been reported, although their frequency is uncertain.⁴

The evaluation of pretest probability of deep-vein thrombosis and pulmonary thromboembolism can be challenging in pregnant women. The “LEFT” rule is used to assess three variables to predict the likelihood of a diagnosis of deep-vein thrombosis in pregnancy: left (L) calf circumference (a difference of ≥ 2 cm or more from the right calf is positive), edema (E), and first-trimester presentation (FT).³² In a validation study in which data from a study designed with a different objective was used, the absence of any of these criteria accurately identified pregnant women who did not have deep-vein thrombosis, although the positive predictive value of having at least one of these findings was low.³³ The modified Wells score (which has a range of 0 to 12.5, with higher scores indicating higher clinical probability) for risk stratification has also been used to assess the probability of pulmonary embolism in pregnant women³⁴; a score of 6 or higher has been associated with a positive predictive value of 36% and a negative predictive value of 100%. More prospective data are needed to better inform the usefulness of these assessments.

TREATMENT

Anticoagulation in pregnancy typically involves unfractionated heparin or low-molecular-weight heparin, which do not cross the placenta or enter breast milk. In contrast, vitamin K antagonists such as warfarin are contraindicated in pregnancy, since they cross the placenta and their use is associated with embryopathy, central nervous system abnormalities, pregnancy loss, and fetal anticoagulation with possible bleeding.¹⁰ However, since warfarin crosses minimally into

breast milk, it can be used in breast-feeding women during the postpartum period.¹⁰

Low-molecular-weight heparins have largely replaced unfractionated heparin for the management of venous thromboembolism in pregnancy. This use is based on extrapolation of efficacy data from trials involving nonpregnant persons,¹⁰ combined with substantial observational data indicating the safety and efficacy of low-molecular-weight heparins in pregnancy.³⁵⁻³⁷

Typical agents include dalteparin (at a dose of 200 IU per kilogram of body weight daily or 100 IU per kilogram twice daily), enoxaparin (1.5 mg per kilogram daily or 1 mg per kilogram twice daily), and tinzaparin (175 units per kilogram daily).^{10,20} In cases in which low-molecular-weight heparin is provided in a prefilled syringe, the dose closest to the patient's weight is administered²⁰; either early or current pregnancy weight is used, since data are lacking to support the use of one weight over the other. Doses are adjusted in patients with clinically significant renal compromise. Monitoring of anti-factor Xa levels is not recommended in routine practice, given uncertainties regarding the relationship between this variable and clinical end points of bleeding or thrombosis and regarding the accuracy and reliability of the measurements.¹⁰

In nonpregnant patients, low-molecular-weight heparins are more effective than unfractionated heparin for the treatment of deep-vein thrombosis and are associated with lower risks of bleeding and death.¹⁰ Low-molecular-weight heparins are not associated with an increased risk of severe postpartum hemorrhage.^{35,37,38} Although it is uncertain whether once-daily or twice-daily dosing is most appropriate for treatment,¹⁰ pharmacokinetic and observational data suggest similar efficacy and safety.^{10,35,37,39}

To minimize the risk of bleeding and allow the option of neuraxial anesthesia, it is prudent to plan delivery in women who are receiving heparin therapy and to discontinue heparin 24 hours before scheduled delivery.^{10,20} Women should be advised to discontinue injections of heparin if labor starts or is suspected. Neuraxial anesthesia is usually deferred until at least 24 hours after the last dose, given a small risk of epidural hematoma associated with administration of neuraxial anesthesia before that time. After delivery, low-molecular-weight heparin should not be ad-

ministered for at least 4 hours after spinal anesthesia or removal of an epidural catheter.²⁰ After delivery, anticoagulant treatment is continued for at least 6 weeks, with a minimum total duration of 3 months.

Data are limited regarding the use of fondaparinux in pregnancy. The data that are available are derived from case reports or case series, mostly in later pregnancy, involving women who have had severe adverse reactions to heparin, such as heparin-induced thrombocytopenia.¹⁰ Small quantities of fondaparinux have been detected in fetal blood after treatment of the mother.^{10,40}

Oral direct thrombin inhibitors such as dabigatran and anti-factor Xa inhibitors such as rivaroxaban should generally be avoided during pregnancy. These agents may cross the placenta with possible adverse fetal effects.^{10,40}

Graduated elastic compression stockings reduce the pain and swelling associated with deep-vein thrombosis. However, a recent randomized trial did not show a benefit from these stockings in preventing the post-thrombotic syndrome.⁴¹

Thrombolysis in pregnancy is reserved for massive life-threatening pulmonary embolism with hemodynamic compromise or for proximal deep-vein thrombosis that is threatening leg viability; in the latter case, catheter-directed thrombolysis may be preferred. Case reports and case series of thrombolytic therapy in pregnant women have suggested that the risk of bleeding complications is similar to that among nonpregnant persons.^{20,42}

Caval filters are sometimes used in women who have recurrent pulmonary embolisms despite adequate anticoagulation or in whom anticoagulation is contraindicated, or in women in whom acute deep-vein thrombosis has developed close to the time of delivery.⁴³ In nonpregnant patients, filters reduce the risk of pulmonary embolism but increase the risk of deep-vein thrombosis,⁴⁴ with no meaningful change in the overall risk of venous thrombosis. Moreover, hazards of caval filters include migration (in >20% of patients), fracture (in approximately 5%), and perforation of the inferior vena cava (in up to 5%).⁴⁴

AREAS OF UNCERTAINTY

High-quality evidence to guide the management of venous thromboembolism during pregnancy is limited. The role of D-dimer testing and of established scoring systems to assess the pretest prob-

ability of venous thrombosis in pregnancy remains unclear. Data are lacking to inform maternal and fetal risks associated with radiation-based tests to detect pulmonary embolisms in pregnant women.

Low-molecular-weight heparin is currently the preferred therapy for venous thromboembolism, but the most appropriate regimen has not been established, including the dosing schedule (once-daily vs. twice-daily), the duration of treatment, and the possibility of dose reduction after initial treatment, nor has the value of monitoring low-molecular-weight heparin activity (anti-factor Xa activity) been determined. The efficacy of and risks associated with newer anticoagulant agents during pregnancy remain to be established. It is unclear how best to prevent the post-thrombotic syndrome.

GUIDELINES

National and international guidelines inform the evaluation and management of venous thromboembolism that occurs during pregnancy.^{10,20,45-48} Key points from the guidelines for which there is consensus are summarized in Table 1. The recommendations in this review are consistent with these guidelines.

CONCLUSIONS AND RECOMMENDATIONS

The woman described in the vignette has multiple risk factors for venous thromboembolism, including a family history (raising the possibility of thrombophilia), a high BMI, age older than 35 years, and probably immobility and dehydration associated with morning sickness. Compression duplex ultrasonographic examination should be performed. If this test confirms deep-vein thrombosis, as suspected, pulmonary imaging is not needed, since it would not alter treatment.

The patient should be treated promptly with a dose of low-molecular-weight heparin according to her weight. Although data are lacking to directly compare once-daily dosing with twice-daily dosing, and either is acceptable, I prefer twice-daily administration for the initial management (since there is greater clinical experience with this regimen) and conversion to once-daily dosing after several weeks.

I would plan delivery with induction at term, temporarily discontinuing the use of low-molec-

Table 1. Summary of Recommendations for Which There is Consensus and Uncertainties and Variations in Guidelines for the Management of Venous Thromboembolism in Pregnancy.***Recommendations for which there is consensus**

Primary diagnostic techniques

- Compression duplex ultrasonography
- Ventilation–perfusion lung scanning

Anticoagulant treatment

- Generally low-molecular-weight heparin (weight-based dose) instead of unfractionated heparin
- Avoid the use of coumarins in antenatal period
- Low-molecular-weight heparin, unfractionated heparin, and coumarins can be used in breast-feeding mothers

Graduated compression stockings for symptom relief in deep-vein thrombosis

Treatment for a minimum of 3 to 6 mo in total and until at least 6 wk post partum

Monitoring of platelet count for heparin-induced thrombocytopenia

- Not recommended in women treated exclusively with low-molecular-weight heparin
- Recommended in women treated with unfractionated heparin

Discontinuation of heparin for 24 hr before induction of labor or cesarean section in women receiving treatment doses to allow delivery and provision of neuraxial anesthesia

Thrombolysis reserved for massive life-threatening pulmonary embolism with hemodynamic compromise or with proximal deep-vein thrombosis threatening leg viability

Caval filters restricted to women with recurrent venous thromboembolism despite therapeutic anticoagulation, since benefits are uncertain, or in women in whom anticoagulation is contraindicated

Uncertainties and variations in guidelines regarding anticoagulant management and monitoring

Whether once-daily or twice-daily low-molecular-weight heparin administration is preferred; all guidelines indicate that both are acceptable

Whether the dose should be adjusted as pregnancy advances; only one guideline specifically recommends dose reduction to intermediate dose (50 to 75% of full treatment dose) or prophylactic dose after initial (3 mo) treatment

* Data are from Bates et al.,¹⁰ Royal College of Obstetricians and Gynaecologists,²⁰ James,⁴⁵ Chan et al.,⁴⁶ Royal College of Obstetricians and Gynaecologists,⁴⁷ and McLintock et al.⁴⁸

ular-weight heparin to minimize the risk of bleeding and permit neuraxial anesthesia if required. Treatment with low-molecular-weight heparin should be restarted after delivery and at least 4 hours after the removal of the epidural catheter. I would continue postpartum anticoagulation for 6 weeks with either low-molecular-weight heparin or coumarin, according to the patient's preference. Despite the patient's family history, I would not perform thrombophilia screening, since this

would not influence subsequent care. Pregnancy-associated venous thromboembolism is a strong risk factor for recurrence, and I would recommend thromboprophylaxis in any subsequent pregnancy from the time the pregnancy is detected until at least 6 weeks post partum.

Dr. Greer reports receiving lecture fees from Sanofi and LEO Pharma. No other potential conflict of interest relevant to this article was reported.

Disclosure forms provided by the author are available with the full text of this article at NEJM.org.

REFERENCES

1. Centre for Maternal and Child Enquiries (CMACE). Saving mothers' lives: reviewing maternal deaths to make motherhood safer: 2006–08 — the Eighth Report of the Confidential Enquiries into Maternal Deaths in the United Kingdom. *BJOG* 2011;118:Suppl 1:57-64.
2. Wik HS, Jacobsen AF, Sandvik L, Sandset PM. Prevalence and predictors for post-thrombotic syndrome 3 to 16 years after pregnancy-related venous thrombosis: a population-based, cross-sectional, case-control study. *J Thromb Haemost* 2012;10:840-7.
3. Kane EV, Calderwood C, Dobbie R, Morris CA, Roman E, Greer IA. A population-based study of venous thrombosis in pregnancy in Scotland 1980-2005. *Eur J Obstet Gynecol Reprod Biol* 2013;169:223-9.
4. Greer IA. Thrombosis in pregnancy: updates in diagnosis and management. *Hematology Am Soc Hematol Educ Program* 2012;2012:203-7.
5. Heit JA, Kobbervig CE, James AH, Pettersen TM, Bailey KR, Melton LJ III. Trends in the incidence of venous thromboembolism during pregnancy or postpartum: a 30-year population-based study. *Ann Intern Med* 2005;143:697-706.

6. Gherman RB, Goodwin TM, Leung B, Byrne JD, Hethumumi R, Montoro M. Incidence, clinical characteristics, and timing of objectively diagnosed venous thromboembolism during pregnancy. *Obstet Gynecol* 1999;94:730-4.
7. James AH, Tapson VF, Goldhaber SZ. Thrombosis during pregnancy and the postpartum period. *Am J Obstet Gynecol* 2005;193:216-9.
8. Kamel H, Navi BB, Sriram N, Hovsepian DA, Devereux RB, Elkind MS. Risk of a thrombotic event after the 6-week postpartum period. *N Engl J Med* 2014;370:1307-15.
9. Jacobsen AF, Skjeldestad FE, Sandset PM. Incidence and risk patterns of venous thromboembolism in pregnancy and puerperium — a register-based case-control study. *Am J Obstet Gynecol* 2008;198(2):e1-e7.
10. Bates SM, Greer IA, Middeldorp S, Veenstra DL, Prabulos AM, Vandvik PO. VTE, thrombophilia, antithrombotic therapy, and pregnancy: Antithrombotic Therapy and Prevention of Thrombosis, 9th ed: American College of Chest Physicians Evidence-Based Clinical Practice Guidelines. *Chest* 2012;141:2 Suppl:e691S-e736S.
11. Robertson L, Wu O, Langhorne P, et al. Thrombophilia in pregnancy: a systematic review. *Br J Haematol* 2006;132:171-96.
12. James AH, Jamison MG, Brancaccio LR, Myers ER. Venous thromboembolism during pregnancy and the postpartum period: incidence, risk factors, and mortality. *Am J Obstet Gynecol* 2006;194:1311-5.
13. Jacobsen AF, Skjeldestad FE, Sandset PM. Ante- and postnatal risk factors of venous thrombosis: a hospital-based case-control study. *J Thromb Haemost* 2008;6:905-12.
14. Chan WS, Ray JG, Murray S, Coady GE, Coates G, Ginsberg JS. Suspected pulmonary embolism in pregnancy: clinical presentation, results of lung scanning, and subsequent maternal and pediatric outcomes. *Arch Intern Med* 2002;162:1170-5.
15. Shahir K, Goodman LR, Tali A, Thorsen KM, Hellman RS. Pulmonary embolism in pregnancy: CT pulmonary angiography versus perfusion scanning. *AJR Am J Roentgenol* 2010;195:W214-W120.
16. Hull RD, Raskob GE, Carter CJ. Serial impedance plethysmography in pregnant patients with clinically suspected deep-vein thrombosis: clinical validity of negative findings. *Ann Intern Med* 1990;112:663-7.
17. Bates SM, Jaeschke R, Stevens SM, et al. Diagnosis of DVT: Antithrombotic Therapy and Prevention of Thrombosis, 9th ed: American College of Chest Physicians Evidence-Based Clinical Practice Guidelines. *Chest* 2012;141:2 Suppl:e351S-e418S.
18. Le Gal G, Kercret G, Ben Yahmed K, et al. Diagnostic value of single complete compression ultrasonography in pregnant and postpartum women with suspected deep vein thrombosis: prospective study. *BMJ* 2012;344:e2635.
19. Chan WS, Spencer FA, Lee AY, et al. Safety of withholding anticoagulation in pregnant women with suspected deep vein thrombosis following negative serial compression ultrasound and iliac vein imaging. *CMAJ* 2013;185:E194-E200.
20. Green-top Guideline No. 37b — thromboembolic disease in pregnancy and the puerperium: acute management. London: Royal College of Obstetricians and Gynaecologists, April 2015 (<https://www.rcog.org.uk/globalassets/documents/guidelines/gtg-37b.pdf>).
21. Scarsbrook AF, Evans AL, Owen AR, Gleeson FV. Diagnosis of suspected venous thromboembolic disease in pregnancy. *Clin Radiol* 2006;61:1-12.
22. Ridge CA, McDermott S, Freyne BJ, Brennan DJ, Collins CD, Skehan SJ. Pulmonary embolism in pregnancy: comparison of pulmonary CT angiography and lung scintigraphy. *AJR Am J Roentgenol* 2009;193:1223-7.
23. Remy-Jardin M, Remy J. Spiral CT angiography of the pulmonary circulation. *Radiology* 1999;212:615-36.
24. Allen C, Demetriades T. Radiation risk overestimated. *Radiology* 2006;240:613-4.
25. Hurwitz LM, Yoshizumi TT, Goodman PC, et al. Radiation dose savings for adult pulmonary embolus 64-MDCT using bismuth breast shields, lower peak kilovoltage, and automatic tube current modulation. *AJR Am J Roentgenol* 2009;192:244-53.
26. Cutts BA, Dasgupta D, Hunt BJ. New directions in the diagnosis and treatment of pulmonary embolism in pregnancy. *Am J Obstet Gynecol* 2013;208:102-8.
27. Groves AM, Yates SJ, Win T, et al. CT pulmonary angiography versus ventilation-perfusion scintigraphy in pregnancy: implications from a UK survey of doctors' knowledge of radiation exposure. *Radiology* 2006;240:765-70.
28. Nguyen CP, Goodman LH. Fetal risk in diagnostic radiology. *Semin Ultrasound CT MR* 2012;33:4-10.
29. Bourjeily G, Paidas M, Khalil H, Rosene-Montella K, Rodger M. Pulmonary embolism in pregnancy. *Lancet* 2010;375:500-12.
30. Schembri GP, Miller AE, Smart R. Radiation dosimetry and safety issues in the investigation of pulmonary embolism. *Semin Nucl Med* 2010;40:442-54.
31. Khalafallah AA, Morse M, Al-Barzan AM, et al. D-Dimer levels at different stages of pregnancy in Australian women: a single centre study using two different immunoturbidimetric assays. *Thromb Res* 2012;130(3):e171-e177.
32. Chan WS, Lee A, Spencer FA, et al. Predicting deep venous thrombosis in pregnancy: out in "LEFt" field? *Ann Intern Med* 2009;151:85-92.
33. Righini M, Jobic C, Boehlen F, et al. Predicting deep venous thrombosis in pregnancy: external validation of the LEFT clinical prediction rule. *Haematologica* 2013;98:545-8.
34. O'Connor C, Moriarty J, Walsh J, Murray J, Coulter-Smith S, Boyd W. The application of a clinical risk stratification score may reduce unnecessary investigations for pulmonary embolism in pregnancy. *J Matern Fetal Neonatal Med* 2011;24:1461-4.
35. Greer IA, Nelson-Piercy C. Low-molecular-weight heparins for thromboprophylaxis and treatment of venous thromboembolism in pregnancy: a systematic review of safety and efficacy. *Blood* 2005;106:401-7.
36. Romualdi E, Dentali F, Rancan E, et al. Anticoagulant therapy for venous thromboembolism during pregnancy: a systematic review and a meta-analysis of the literature. *J Thromb Haemost* 2013;11:270-81.
37. Nelson-Piercy C, Powrie R, Borg JY, et al. Tinzaparin use in pregnancy: an international, retrospective study of the safety and efficacy profile. *Eur J Obstet Gynecol Reprod Biol* 2011;159:293-9.
38. Knol HM, Schultinge L, Veeger NJGM, Kluin-Nelemans HC, Erwich JJHM, Meijer K. The risk of postpartum hemorrhage in women using high dose of low-molecular-weight heparins during pregnancy. *Thromb Res* 2012;130:334-8.
39. Patel JP, Green B, Patel RK, Marsh MS, Davies JG, Arya R. Population pharmacokinetics of enoxaparin during the antenatal period. *Circulation* 2013;128:1462-9.
40. Tang AW, Greer IA. A systematic review on the use of new anticoagulants in pregnancy. *Obstet Med* 2013;6:64-71.
41. Kahn SR, Shapiro S, Wells PS, et al. Compression stockings to prevent post-thrombotic syndrome: a randomised placebo-controlled trial. *Lancet* 2014;383:880-8.
42. te Raa GD, Ribbert LSM, Snijder RJ, Biesma DH. Treatment options in massive pulmonary embolism during pregnancy; a case-report and review of literature. *Thromb Res* 2009;124:1-5.
43. Milford W, Chadha Y, Lust K. Use of a retrievable inferior vena cava filter in term pregnancy: case report and review of literature. *Aust N Z J Obstet Gynaecol* 2009;49:331-3.
44. Kearon C, Akl EA, Comerota AJ, et al. Antithrombotic therapy for VTE disease: antithrombotic therapy and prevention of thrombosis, 9th ed: American College of Chest Physicians evidence-based clinical practice guidelines. *Chest* 2012;141:2 Suppl:e419S-e494S.
45. James A. Practice bulletin no. 123: thromboembolism in pregnancy. *Obstet Gynecol* 2011;118:718-29.

46. Chan WS, Rey E, Kent NE, et al. Venous thromboembolism and antithrombotic therapy in pregnancy. *J Obstet Gynaecol Can* 2014;36:527-53.
47. Green-top Guideline No. 37a — reducing the risk of thrombosis and embolism during pregnancy and the puerperium. London: Royal College of Obstetricians and Gynaecologists, April 2015 (<https://www.rcog.org.uk/globalassets/documents/guidelines/gtg-37a.pdf>).
48. McLintock C, Brighton T, Chunilal S, et al. Recommendations for the diagnosis and treatment of deep venous thrombosis and pulmonary embolism in pregnancy and the postpartum period. *Aust N Z J Obstet Gynaecol* 2012;52:14-22.

Copyright © 2015 Massachusetts Medical Society.