

## Trauma Reports

### TRAUMA AIRWAY MANAGEMENT

Cheryl Lynn Horton, MD, Calvin A. Brown III, MD, and Ali S. Raja, MD, MBA, MPH

Department of Emergency Medicine, Brigham and Women's Hospital, Boston, Massachusetts

Reprint Address: Ali S. Raja, MD, MBA, MPH, Department of Emergency Medicine, Brigham and Women's Hospital 75 Francis Street, Neville House 312E, Boston, MA 02115

**Abstract—Background:** Airway management in a trauma patient can be particularly challenging when both a difficult airway and the need for rapid action collide. The provider must evaluate the trauma patient for airway difficulty, develop an airway management plan, and be willing to act quickly with incomplete information. **Discussion:** Thorough knowledge of airway management algorithms will assist the emergency physician in providing optimal care and offer a rapid and effective treatment plan. **Conclusions:** Using a case-based approach, this article reviews initial trauma airway management strategies along with the rationale for evidence-based treatments. © 2014 Elsevier Inc.

**Keywords—trauma; airway; intubation; tracheobronchial injury; tracheal injury**

#### CASE REPORT

A 34-year-old man presented to the emergency department (ED) of a Level I trauma center via emergency medical services (EMS) after a motor vehicle collision. He was the unrestrained driver in a high-speed single-car accident with significant front-end damage and a prolonged extrication period. Witnesses reported that he was swerving for approximately half a mile before he eventually ran off of the road and struck a tree. Upon EMS arrival, they noted that he was confused and exhibited repetitive speech. Prehospital vitals revealed a blood pressure of 110/89 mm Hg, a pulse of 112 beats/min (bpm), a respiratory rate of 18 breaths/min, and an oxygen

saturation of 97% on room air. He had sustained obvious head, face, and chest injuries. He was placed in a cervical collar, extricated, and brought to the ED on a backboard.

Immediately upon arrival to the ED, his primary survey was notable for incoherent speech and a hoarse voice. He had decreased breath sounds on the right, 2+ symmetric pulses throughout, and visible right chest wall ecchymosis. His initial ED vitals signs revealed a blood pressure of 95/70 mm Hg, a pulse of 115 bpm, a temperature of 37.2°C, and an oxygen saturation of 96% on room air. His Glasgow Coma Scale (GCS) score was 11, as he was only opening his eyes to vocal commands and speaking incoherently, yet was moving all of his extremities in response to painful stimuli. An extended focused abdominal sonography for trauma (E-FAST) examination was only positive for free fluid in Morrison's pouch and demonstrated normal lung sliding bilaterally. Two large-bore peripheral lines were established and a cardiac monitor was applied.

His secondary survey was notable for a large 15-cm laceration extending from his forehead to his occipital scalp, with active bleeding and a moderate amount of blood on the backboard. His pupils were equal and reactive. Upon removal of the cervical collar, he was noted to have ecchymosis with mild edema of his anterior neck, as well as subcutaneous emphysema that extended down to his nipple line on the right. His trachea was midline but seemed tender to palpation. No stridor was audible, but he had decreased breath sounds on the right and was tender on his right chest wall and in his right upper

RECEIVED: 25 September 2012; FINAL SUBMISSION RECEIVED: 20 September 2013;  
ACCEPTED: 17 November 2013

abdominal quadrant. The remainder of his examination was unremarkable and he continued to be able to move all four extremities in response to pain. His vital signs were rechecked and found to be unchanged.

A portable chest x-ray study was notable for an opacity in the right middle lobe, concerning for a pulmonary contusion but did not show a pneumothorax or pleural effusion. His pelvis x-ray study was normal. Given his injuries, the emergency physician and trauma surgeon decided that he should have his airway protected before going to computed tomography (CT) for evaluation of his suspected neurologic, thoracic, and intra-abdominal injuries.

## DISCUSSION

### *Initial Evaluation and Intervention*

Airway management in the trauma patient can be challenging and, for some patients, the need to act urgently and decisively can be the difference between survival and death. Tenuous hemodynamics, cervical immobility, and direct airway trauma often complicate decision making. Typical intubation methods can be difficult or impossible in patients with rapid oropharyngeal hemorrhage, reduced oral access, or laryngotracheal injuries.

Although some decisions are specific to trauma intubations, sound airway-management principles that are common to all intubations still constitute a foundation for success. Deciding to intubate is the first step. Although this is intuitive for many patients, the need for intubation might not be initially obvious in some patients. There are three main indications for emergency intubation that can be uncovered by asking the following questions: 1) Is there a failure to maintain or protect the airway? 2) Is there a failure of oxygenation or ventilation? or 3) Is there a need for intubation based on the anticipated clinical course? (1).

A failure to maintain one's airway is not always clinically obvious. One approach is to calculate the patient's GCS score. A GCS score  $\leq 8$  in the absence of a reversible cause is a clinical coma and these patients generally require intubation (2–4). Most patients with a GCS score  $\leq 12$  will have sustained significant brain injury and often will also require intubation. The inability to protect one's airway can be subtle, but in trauma patients this usually occurs in the setting of depressed mental status caused by head trauma, hypovolemic shock, or ingestion of drugs or alcohol. Clinicians can test for airway protection by evaluating phonation and a patient's ability to swallow and handle secretions. The gag reflex should never be assessed in a critically injured, immobilized trauma patient, as doing so can provoke vomiting and worsen the situation. In addition,

this reflex is weak in up to 25% of the normal adult population and its absence does not necessarily indicate the need for intubation (2). Failure to appropriately oxygenate and ventilate can be assessed clinically by evaluating a patient's respiratory effort, oxygen saturation, and overall sense of the patient's injuries. The anticipated clinical course helps to guide the decision to intubate in patients who do not have an immediate problem with airway protection, ventilatory effort, or oxygenation. It is better to err on the side of intubating early and securing a potentially threatened airway than observing the patient with a false sense of security originating from momentarily adequate oxygenation and ventilation. In addition, the patient's trajectory may include inevitable intubation, and the opportunity to intubate early allows a more controlled and planned approach. For example, a blunt trauma patient with an open femur fracture, intractable pain, and agitation may have an indication for intubation in order to humanely and safely perform a thorough trauma and radiologic evaluation, even in the absence of oxygenation difficulties or direct airway trauma.

Supplemental oxygenation should be started immediately for any hypoxic trauma patient, especially those with suspected brain injury (5). Nasal cannula oxygenation may suffice for those with a mild oxygen debt but, generally, face-mask oxygenation with a reservoir at 15 L/min flow is used. If intubation is planned, pre-oxygenation should be started by having the patient take full tidal volume breaths of high concentration oxygen for 2–3 minutes (6). For patients predicted to desaturate rapidly, nasal cannula oxygen should be left in place during the apneic phase of intubation, as this can significantly prolong the period of safe apnea (7,8).

### *Intubation of the Trauma Patient*

Once the decision to intubate a trauma patient has been made, choosing the best method is paramount and based on the predicted timeline, clinical scenario, and available equipment. For all patients, a difficult airway (DA) assessment is necessary before rapid sequence intubation (RSI) with neuromuscular blockade. There are a number of DA assessment mnemonics that are easy to remember and can be applied quickly to most patients at the bedside (1). They evaluate for potential difficulty with direct laryngoscopy, rescue bag and mask ventilation, use of an extraglottic device, and performance of a surgical airway. The acronym LEMON (Figure 1) assesses for difficulty with direct laryngoscopy and has been validated in one ED study (9). The MOANS mnemonic (Figure 2) is made up of a well-validated set of patient characteristics known to result in difficult mask ventilation. These should be recognized early, as meticulous bagging

<b>L</b>	Look externally (gestalt)
<b>E</b>	Evaluate 3-3-2 rule
<b>M</b>	Mallampati scale
<b>O</b>	Obstruction/Obesity
<b>N</b>	Neck mobility

**Figure 1. LEMON for difficult direct laryngoscopy assessment.**

technique will be necessary to effectively ventilate patients with red flags on their MOANS evaluation (1,10).

For patients without obvious difficult airway attributes, RSI is generally believed to be the safest and most reliable way to intubate a patient. With complete sedation and paralysis, RSI also provides the greatest chance for a successful intubation (11).

When a difficult intubation is anticipated, an algorithmic approach should be used and is dictated by a patient's hemodynamic stability and the urgency of the intubation (Figure 3). First and foremost, if a difficult trauma airway is anticipated and time allows for it, the emergency physician should strongly consider calling anesthesia or surgical colleagues to the bedside, especially if advanced fiberoptic techniques or cricothyrotomy will potentially be required. In some urgent scenarios, patients can even be moved to the operating room (OR) for intubation, where induction with an inhalational anesthetic can be used.

Next, the emergency physician should assess the patient's rate of airway or clinical deterioration. If the need for intubation is immediate and a full airway assessment or the luxury of extra staff, equipment, and management planning are not possible, then the provider is "forced to act." In this situation, one "best attempt" by the most experienced operator, with the best device, using RSI, is appropriate knowing that there is immediate recourse to a surgical airway should that one attempt fail (1).

For difficult intubations in which there is time to plan, but the nature of the airway complexities make chances of successful laryngoscopy or rescue ventilation unlikely, then an "awake" intubation attempt or an awake evaluation of the airway should be performed. An awake intubation involves administration of topical anesthesia, possibly augmented by judicious use of a sedative agent to permit an awake evaluation of the airway with either a conventional laryngoscope, video laryngoscope, or

<b>M</b>	Mask seal
<b>O</b>	Obesity/Obstruction
<b>A</b>	Aged (> 55 years)
<b>N</b>	No teeth
<b>S</b>	Stiff lungs

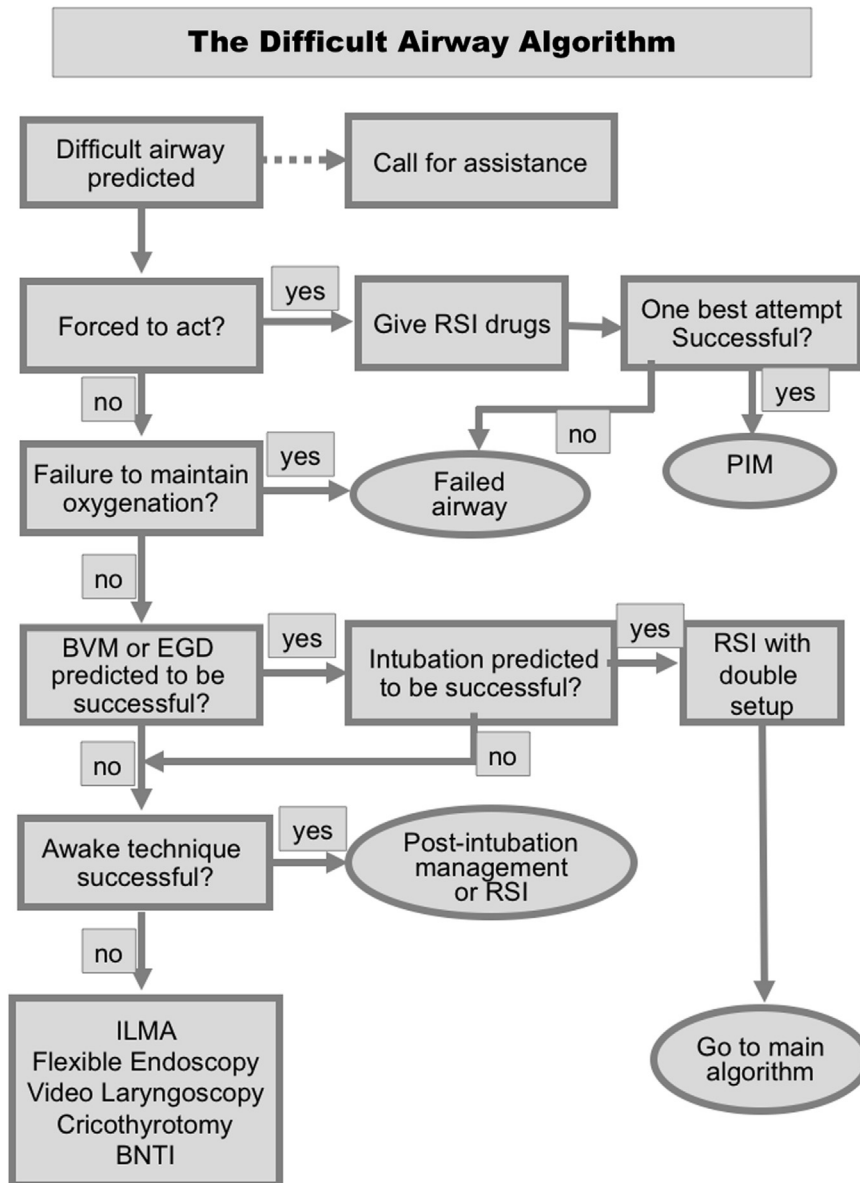
**Figure 2. MOANS for difficult mask ventilation assessment.**

flexible fiberoptic bronchoscope. A patient must be cooperative and able to tolerate this examination for it to be successful. Awake laryngoscopy allows the operators to do one of three things: 1) intubate the patient, 2) visualize the cords and determine that intubation is possible and the patient can be intubated with RSI, or 3) determine that oral intubation is impossible and an alternative approach is necessary.

All patients who have been subjected to significant blunt trauma should be assumed to have a cervical spine injury until it has been excluded. Motor vehicle collisions are the greatest cause of spinal injury, accounting for approximately 50%, followed by falls, athletic injury, and interpersonal violence (12). Patients with suspected or proven cervical spine injury should be intubated with the help of a second provider performing in-line cervical spine stabilization. Although there is no credible evidence that RSI and direct laryngoscopy result in clinically significant cervical spine movement, some devices are thought to be better for patients at high risk for cervical spine injury (13–15). Optically and video-enhanced devices with curved architecture, such as the Airtraq and GlideScope video laryngoscopes, have proven to be successful in trauma patients and may reduce cervical spine movement compared with direct laryngoscopy (16,17). For conventional laryngoscopy, the anterior portion of the collar should be opened while an assistant holds the cervical spine. If the cervical collar is left fully engaged, there may be limitations to mouth opening that can make intubation more difficult, and there is no evidence that this reduces cervical spine movement (14,18,19).

Medication choice and the timing of administration is an important aspect of a successful intubation. Although pretreatment medications have never been proven to result in improved outcomes, there are theoretical and common sense reasons why these agents, in selected patients without contraindications, would be beneficial. For head-injured patients, lidocaine (1.5 mg/kg) and fentanyl (2–3 mg/kg) administered 3–5 min before the induction agent, can be used in an attempt to minimize the rise in intracranial pressure (ICP) that accompanies laryngeal manipulation. The mechanism by which lidocaine works is poorly understood but it is thought to attenuate a direct, neurally mediated reflex after laryngoscopy, while fentanyl has been shown, in a dose-dependent fashion, to blunt the reflex sympathetic response to laryngoscopy, further attenuating spikes in heart rate and blood pressure that can be seen with laryngeal manipulation (1,20).

Etomidate and ketamine are the most commonly used induction agents for trauma patients requiring intubation. Etomidate (0.3 mg/kg) has beneficial hemodynamic stability during RSI and causes virtually no change in mean arterial blood pressure in normal and hypovolemic patients (21). In patients with frank shock, however, the



**Figure 3. The difficult airway algorithm. BNTI = blind nasotracheal intubation; BVM = bag-valve mask; EGD = extraglottic device; ILMA = intubating laryngeal mask airway; PIM = post intubation management; RSI = rapid sequence intubation. (From Walls R, Murphy M. Manual of emergency airway management. 4th ed. Lippincott Williams & Wilkins; 2012. Reprinted with permission.)**

dose should be reduced to 0.15 mg/kg and in morbidly obese patients, dosing should be based on lean body weight, as large doses (two to three times the induction dose) can cause hypotension (22). Etomidate appears to have some cerebral protective effect and can significantly lower ICP without adverse effects on perfusion pressure (23). Studies show that there is transient adrenal suppression after a single dose of etomidate, although the significance of this in trauma patients is unknown and current literature evaluating etomidate and trauma patients suffers from irrecoverable design and analysis flaws (24,25). However, results from a recent randomized study comparing ketamine and etomidate in critical

illness show no difference in patient mortality (26). Nevertheless, ketamine at 1.5 mg/kg is a reasonable alternative to etomidate. It exhibits cardiovascular stability and maintains protective airway reflexes and can be used to facilitate airway evaluations or awake intubations. Bronchorrhea may be attenuated with a drying agent such as glycopyrrolate or atropine (27). In patients with severe hemodynamic compromise, the dose should be reduced to 1 mg/kg. In patients with refractory shock, ketamine depresses myocardial contractility and must be used with caution (28,29).

Succinylcholine is the paralytic of choice for RSI of the polytrauma patient. Competitive neuromuscular

blocking agents like rocuronium (1.0 mg/kg) achieve intubating conditions nearly as rapidly as succinylcholine and should be used if a contraindication to succinylcholine exists, however, the duration of paralysis is approximately 45 min (30–32). For this reason, succinylcholine, with its rapid onset and shorter duration of action, remains the drug of choice for emergency intubation of trauma patients.

Overall resuscitation from the hypovolemic state must occur in parallel with preparation for intubation. Crystalloids can be infused as the first 2 L of fluid during resuscitation but should be replaced with blood if shock is ongoing or worsening. In an unstable multiple trauma patient, if the need for intubation is not imminent, volume resuscitation should take precedence in order to improve hemodynamics and allow more pharmacologic options during RSI.

### TRACHEOBRONCHIAL INJURIES

Although traumatic tracheobronchial injuries are rare, they should be suspected in patients with blunt or penetrating injury to the neck or chest, especially with external evidence of injury, including pain, ecchymosis, swelling, or soft-tissue crepitus. The incidence of traumatic tracheobronchial injuries is estimated to be 0.5%–2% of patients with blunt trauma patients and 3%–8% of penetrating cervical trauma patients (33,34). Patients with complete traumatic tracheobronchial transections have a high mortality rate and often die before making it to the ED. In one study, 78% of patients died in the field and 21% of patients died within 2 h of hospital arrival (35). Kirsh et al. have proposed several mechanisms for these injuries, including a forced compression of the chest tearing the carina from the bronchus, a shear force from a deceleration injury causing the freely mobile lungs to tear from the bronchus or trachea, and compression of the chest against a closed glottis causing a tear to the membranous trachea (36,37). Patients often present with dyspnea or respiratory distress (76%–100%) and hoarseness or dysphonia (46%) (38–40). Common signs of tracheobronchial injuries are pneumothorax (20%–50%), subcutaneous emphysema (35%–85%), and hemoptysis (14%–25%) (41). Although CT scans detect roughly 90% of injuries, bronchoscopy is the gold standard for diagnosis. Injury severity and treatment options can also be determined using bronchoscopy as well (41).

Patients who make it to the hospital with a tracheobronchial injury are alive because they have either a minor injury not likely to be life threatening or a partial transection. If they have the latter, actions by the emergency physician can be either heroic or quickly result in death. Paramount in managing suspected partial tracheal transections is to avoid converting the injury to a complete transection. Positive pressure ventilation or an unguided

placement of a large-bore tracheal tube can complete a partial tracheal transection. In these patients, successful tracheal intubation is best accomplished in the OR, with inhalational anesthetics, a skilled fiberoptic intubator and a small tracheal tube placed distal to the level of the injury. If the airway must be managed before the OR, then an awake technique should be done with topical anesthesia and sedation, as needed, to complete the procedure. This is most easily done in stable, cooperative patients, however, the emergency physician must be ready to deal with agitation and airway collapse should they occur during the awake attempt. In these situations, preparation for an immediate tracheostomy or cricothyrotomy must be done concurrently with the intubation attempt. It is important to recognize that cricothyrotomy is unlikely to be successful, as the tracheal laceration is often distal to the tracheostomy tube. A thin, flexible fiberoptic intubating bronchoscope with a 6.0 or 6.5 tracheal tube is the best option with early recourse to a surgical airway should the intubation fail and the patient rapidly deteriorates.

Definitive management of a tracheobronchial injury is largely dictated by the location and severity of the injury. Historically, surgical repair was the treatment of choice, but recently, removable stents have been used to manage large tears. Conservative management is possible if the laceration is located in the upper or middle portion of the trachea and an endotracheal tube or tracheostomy tube can be placed distal to the level of the tracheal laceration (42).

#### *Additional ED Management, Summary, and Prognosis*

Initial management steps in our trauma patient were focused on fluid resuscitation and the control of ongoing blood loss. The scalp laceration was stapled immediately to prevent any additional bleeding and 1 unit of O+ uncrossmatched packed red blood cells was administered to correct the patient's relative hypotension due to hypovolemia.

The decision to intubate the patient before transfer to CT was made because the patient had a GCS of 11 and his projected clinical course included a possible operative repair of a presumed tracheal injury. In addition, respiratory failure and hypoxia were likely, given his pulmonary contusion and ongoing resuscitation requirements. Although he was hypoxic and hypotensive, a chest tube thoracostomy was not performed because his E-FAST was negative.

The anterior neck was prepared with Betadine as part of a double setup in case a surgical tracheostomy had been required. The patient received topical anesthesia with nebulized lidocaine and glycopyrrolate to minimize bronchorrhoea, as well as a half dose of etomidate (0.5 mg/kg). The fiberoptic bronchoscope was loaded with an



endotracheal tube and inserted through a Berman airway. A partial tracheal laceration was visualized approximately 4 cm proximal to the carina. The fiberoptic bronchoscope was inserted to the level of the carina to verify that the tracheal disruption had been passed, and a 6.0 endotracheal tube was gently passed in order to minimize any further tracheal disruption. No air leak was noted after insufflation of the endotracheal balloon and the patient was then sedated with fentanyl and midazolam.

The CT scan of the head did not show any acute intracranial hemorrhage and there were no fractures of the cranium or cervical spine. The CT of the chest and abdomen showed subcutaneous air in the soft tissue of the neck and upper chest in addition to pneumomediastinum. A moderate-sized right middle lobe opacity consistent with a contusion, and a grade 2 liver laceration without active extravasation were also appreciated. Significant laboratory values include a hemoglobin of 8.7 g/dL, base deficit of 18 mEq/L, and a lactate of 4.1 mmol/L.

The patient was then transferred to the surgical intensive case unit for further resuscitation and management.

#### AUTHORS' RECOMMENDATIONS

Trauma patients who need an airway intervention require rapid evaluation for difficult airway attributes, management via a preplanned airway algorithm (including rescue techniques in the event of failure), and a willingness to act quickly with incomplete information. In most cases, the need to intervene is apparent, however, certain situations can mislead the evaluating physician, lulling them into the misperception that an airway is "stable." Many trauma patients can initially appear so; they maintain patent airways and breathe spontaneously until the culmination of their injuries cause them to deteriorate rapidly. Soft-tissue swelling, hematoma, or subcutaneous air can cause dramatic and potentially lethal airway distortion, even though external findings remain unremarkable, until the patient suddenly decompensates. The imperative with any traumatized airway is for early assessment and decisive action. Like other difficult airways, trauma intubations require clarity of thought, sound decision making based on accepted management algorithms, use of fiberoptic, video, and surgical techniques when called for, and a low threshold to ask for specialty assistance. Delay or observation, although initially seeming prudent, can lead to catastrophic airway compromise and make airway management much more difficult than if it had been undertaken earlier.

#### CONCLUSIONS

Our patient was extubated on hospital day (HD) 6. He was moved to a general surgical floor on HD 8, but remained

hospitalized for 2 weeks before being discharged to a rehabilitation facility. A follow-up bronchoscopy showed a well-healed trachea without stricture.

#### REFERENCES

1. Walls R, Murphy M. *Manual of emergency airway management*. 4th ed. Philadelphia: Lippincott Williams & Wilkins; 2012.
2. Chan B, Gaudry P, Grattan-Smith TM, McNeil R. The use of Glasgow Coma Scale in poisoning. *J Emerg Med* 1993;11:579–82.
3. Moulton C, Pennycook A, Makower R. Relation between Glasgow Coma Scale and the gag reflex. *BMJ* 1991;303(6812):1240–1.
4. Bleach NR. The gag reflex and aspiration: a retrospective analysis of 120 patients assessed by videofluoroscopy. *Clin Otolaryngol Allied Sci* 1993;18:303–7.
5. Chesnut RM, Marshall LF, Klauber MR, et al. The role of secondary brain injury in determining outcome from severe head injury. *J Trauma* 1993;34:216–22.
6. Baraka AS, Taha SK, El-Khatib MF, Massouh FM, Jabbour DG, Alameddine MM. Oxygenation using tidal volume breathing after maximal exhalation. *Anesth Analg* 2003;97:1533–5.
7. Ramachandran SK, Cosnowski A, Shanks A, Turner CR. Apneic oxygenation during prolonged laryngoscopy in obese patients: a randomized, controlled trial of nasal oxygen administration. *J Clin Anesth* 2010;22:164–8.
8. Weingart SD, Levitan RM. Preoxygenation and prevention of desaturation during emergency airway management. *Ann Emerg Med* 2012;59:165–175.
9. Reed MJ, Dunn MJG, McKeown DW. Can an airway assessment score predict difficulty at intubation in the emergency department? *Emerg Med J* 2005;22:99–102.
10. Langeron O, Masso E, Huraux C, et al. Prediction of difficult mask ventilation. *Anesthesiology* 2000;92:1229–36.
11. Walls RM, Brown CA 3rd, Bair AE, Pallin DJ, NEAR II Investigators. Emergency airway management: a multi-center report of 8937 emergency department intubations. *J Emerg Med* 2011;41:347–54.
12. Burney RE, Maio RF, Maynard F, Karunas R. Incidence, characteristics, and outcome of spinal cord injury at trauma centers in North America. *Arch Surg* 1993;128:596–9.
13. Gerling MC, Davis DP, Hamilton RS, et al. Effects of cervical spine immobilization technique and laryngoscope blade selection on an unstable cervical spine in a cadaver model of intubation. *Ann Emerg Med* 2000;36:293–300.
14. Majernick TG, Bieniek R, Houston JB, Hughes HG. Cervical spine movement during orotracheal intubation. *Ann Emerg Med* 1986;15:417–20.
15. Walls RM. Airway management in the blunt trauma patient: how important is the cervical spine? *Can J Surg* 1992;35:27–30.
16. Arslan ZI, Yildiz T, Baykara ZN, Solak M, Tokar K. Tracheal intubation in patients with rigid collar immobilisation of the cervical spine: a comparison of Airtraq and LMA CTrach devices. *Anaesthesia* 2009;64:1332–6.
17. Kill C, Risse J, Wallot P, Seidl P, Steinfeldt T, Wulf H. Videolaryngoscopy with glidescope reduces cervical spine movement in patients with unsecured cervical spine. *J Emerg Med* 2013;44:750–6.
18. Donaldson WF, Heil BV, Donaldson VP, Silvaggio VJ. The effect of airway maneuvers on the unstable C1–C2 segment. A cadaver study. *Spine* 1997;22:1215–8.
19. Brimacombe J, Keller C, Künzel KH, Gaber O, Boehler M, Pühringer F. Cervical spine motion during airway management: a cinefluoroscopic study of the posteriorly destabilized third cervical vertebrae in human cadavers. *Anesth Analg* 2000;91:1274–8.
20. Splinter WM, Cervenka F. Haemodynamic responses to laryngoscopy and tracheal intubation in geriatric patients: effects of fentanyl, lidocaine and thiopentone. *Can J Anaesth* 1989;36:370–6.
21. Lindeburg T, Spotoft H, Bredgaard Sørensen M, Skovsted P. Cardiovascular effects of etomidate used for induction and in combination with fentanyl-pancuronium for maintenance of anaesthesia in

- patients with valvular heart disease. *Acta Anaesthesiol Scand* 1982; 26:205–8.
22. Shapiro BM, Wendling WW, Ammatturo FJ, et al. Vascular effects of etomidate administered for electroencephalographic burst suppression in humans. *J Neurosurg Anesthesiol* 1998;10:231–6.
  23. Modica PA, Tempelhoff R. Intracranial pressure during induction of anaesthesia and tracheal intubation with etomidate-induced EEG burst suppression. *Can J Anaesth* 1992;39:236–41.
  24. Hildreth AN, Mejia VA, Maxwell RA, Smith PW, Dart BW, Barker DE. Adrenal suppression following a single dose of etomidate for rapid sequence induction: a prospective randomized study. *J Trauma* 2008;65:573–9.
  25. Pallin DJ, Walls RM. The safety of single-dose etomidate. *Intensive Care Med* 2010;36:1268. author reply 1269–70.
  26. Jabre P, Combes X, Lapostolle F, et al. Etomidate versus ketamine for rapid sequence intubation in acutely ill patients: a multicentre randomised controlled trial. *Lancet* 2009;374(9686): 293–300.
  27. Malik JA, Gupta D, Agarwal AN, Jindal SK. Anticholinergic premedication for flexible bronchoscopy: a randomized, double-blind, placebo-controlled study of atropine and glycopyrrolate. *Chest* 2009;136:347–54.
  28. Haas DA, Harper DG. Ketamine: a review of its pharmacologic properties and use in ambulatory anesthesia. *Anesth Prog* 1992;39:61–8.
  29. Waxman K, Shoemaker WC, Lippmann M. Cardiovascular effects of anesthetic induction with ketamine. *Anesth Analg* 1980;59:355–8.
  30. Perry JJ, Lee JS, Sillberg VAH, Wells GA. Rocuronium versus succinylcholine for rapid sequence induction intubation. *Cochrane Database Syst Rev* 2008;(2):CD002788.
  31. Schramm WM, Strasser K, Bartunek A, Gilly H, Spiss CK. Effects of rocuronium and vecuronium on intracranial pressure, mean arterial pressure and heart rate in neurosurgical patients. *Br J Anaesth* 1996;77:607–11.
  32. Kirkegaard-Nielsen H, Caldwell JE, Berry PD. Rapid tracheal intubation with rocuronium: a probability approach to determining dose. *Anesthesiology* 1999;91:131–6.
  33. De la Rocha AG, Kayler D. Traumatic rupture of the tracheobronchial tree. *Can J Surg* 1985;28:68–71.
  34. Angood PB, Attia EL, Brown RA, Mulder DS. Extrinsic civilian trauma to the larynx and cervical trachea—important predictors of long-term morbidity. *J Trauma* 1986;26:869–73.
  35. Beiderlinden M, Adamzik M, Peters J. Conservative treatment of tracheal injuries. *Anesth Analg* 2005;100:210–4.
  36. Kirsh MM, Orringer MB, Behrendt DM, Sloan H. Management of tracheobronchial disruption secondary to nonpenetrating trauma. *Ann Thorac Surg* 1976;22:93–101.
  37. Eastridge CE, Hughes FA Jr, Pate JW, Cole F, Richardson R. Tracheobronchial injury caused by blunt trauma. *Am Rev Respir Dis* 1970;101:230–7.
  38. Kelly JP, Webb WR, Moulder PV, Everson C, Burch BH, Lindsey ES. Management of airway trauma. I: tracheobronchial injuries. *Ann Thorac Surg* 1985;40:551–5.
  39. Rossbach MM, Johnson SB, Gomez MA, Sako EY, Miller OL, Calhoon JH. Management of major tracheobronchial injuries: a 28-year experience. *Ann Thorac Surg* 1998;65:182–6.
  40. Reece GP, Shatney CH. Blunt injuries of the cervical trachea: review of 51 patients. *South Med J* 1988;81:1542–8.
  41. Karmy-Jones R, Wood DE. Traumatic injury to the trachea and bronchus. *Thorac Surg Clin* 2007;17:35–46.
  42. Yopp AC, Eckstein JG, Savel RH, Abrol S. Tracheal stenting of iatrogenic tracheal injury: a novel management approach. *Ann Thorac Surg* 2007;83:1897–9.