

## CLINICAL PRACTICE

Caren G. Solomon, M.D., M.P.H., *Editor*

## Acute Lower Gastrointestinal Bleeding

Ian M. Gralnek, M.D., M.S.H.S., Ziv Neeman, M.D.,  
and Lisa L. Strate, M.D., M.P.H.

*This Journal feature begins with a case vignette highlighting a common clinical problem. Evidence supporting various strategies is then presented, followed by a review of formal guidelines, when they exist. The article ends with the authors' clinical recommendations.*

From the Institute of Gastroenterology and Hepatology (I.M.G.) and Medical Imaging Institute (Z.N.), Emek Medical Center, Afula, and Rappaport Faculty of Medicine, Technion–Israel Institute of Technology, Haifa (I.M.G.) — both in Israel; and the Department of Medicine, Division of Gastroenterology, University of Washington School of Medicine, Seattle (L.L.S.). Address reprint requests to Dr. Gralnek at the Institute of Gastroenterology and Hepatology, Emek Medical Center, 21 Izhak Rabin Blvd., Afula 1834111, Israel, or at [ian\\_gr@clalit.org.il](mailto:ian_gr@clalit.org.il).

N Engl J Med 2017;376:1054-63.

DOI: 10.1056/NEJMc1603455

Copyright © 2017 Massachusetts Medical Society.

**A 71-year-old woman with hypertension, hypercholesterolemia, and ischemic heart disease, who had a cardiac stent placed 4 months earlier, presents to the emergency department with multiple episodes of red or maroon-colored stool mixed with clots during the preceding 24 hours. Current medications include atenolol, atorvastatin, aspirin (81 mg daily), and clopidogrel. On physical examination, the patient is diaphoretic. While she is in a supine position, the heart rate is 91 beats per minute and the blood pressure is 106/61 mm Hg; while she is sitting, the heart rate is 107 beats per minute and the blood pressure is 92/52 mm Hg. The remainder of the examination is unremarkable, except for maroon-colored stool on digital rectal examination. The hemoglobin level is 9.3 g per deciliter, the platelet count 235,000 per cubic millimeter, and the international normalized ratio 1.1. How should this patient's case be further evaluated and managed?**

## THE CLINICAL PROBLEM

**I**N THE UNITED STATES, GASTROINTESTINAL BLEEDING IS THE MOST COMMON cause of hospitalization due to gastrointestinal disease; approximately 30 to 40% of all cases of gastrointestinal bleeding are from a lower gastrointestinal source.<sup>1</sup> In most patients with acute lower gastrointestinal bleeding, the bleeding stops without intervention, and there are no complications. However, advanced age and clinically significant coexisting illnesses are associated with increased morbidity and mortality.<sup>2</sup> Classically, acute lower gastrointestinal bleeding manifests as hematochezia (maroon or red blood passed through the rectum). Uncommonly, lower gastrointestinal bleeding can manifest as melena (black, tarry stools), or, conversely, brisk (rapid) upper gastrointestinal bleeding can manifest as hematochezia. Previously, lower gastrointestinal bleeding was defined as bleeding originating distal to the ligament of Treitz. However, owing to the distinct nature of small-intestinal bleeding (defined as bleeding originating between the ligament of Treitz and the ileocecal valve and now referred to as middle gastrointestinal bleeding), acute lower gastrointestinal bleeding is defined as the onset of hematochezia originating from either the colon or the rectum.<sup>3,4</sup> This review focuses on the management of brisk, large-volume colorectal bleeding.



An audio version  
of this article  
is available at  
[NEJM.org](http://NEJM.org)

## KEY CLINICAL POINTS

## ACUTE LOWER GASTROINTESTINAL BLEEDING

- Colonoscopy should be the initial procedure for most patients presenting with acute lower gastrointestinal bleeding. It should generally be performed within 24 hours after presentation, after hemodynamic resuscitation and colon cleansing.
- Hematochezia in the context of hemodynamic instability may represent an upper gastrointestinal bleeding event; therefore, upper endoscopy should be considered.
- Findings of active bleeding, a nonbleeding visible vessel, or adherent clot should be treated when identified during colonoscopy.
- In patients with persistent bleeding or hemodynamic instability despite resuscitation efforts, radiographic evaluation and angiographic treatment should be considered.
- Low-dose aspirin for primary prevention of cardiovascular events should be stopped in patients with lower gastrointestinal bleeding and should generally not be resumed. Low-dose aspirin for secondary cardiovascular prophylaxis should be continued without interruption.
- In patients receiving dual antiplatelet therapy, aspirin should be continued without interruption; except in patients at high cardiovascular risk, the nonaspirin antiplatelet agent should be withheld for 1 to 7 days.

## STRATEGIES AND EVIDENCE

## INITIAL PATIENT ASSESSMENT

A directed history taking, physical examination, and laboratory evaluation should be performed at the time of patient presentation. Patient assessment and hemodynamic resuscitation should be performed simultaneously.<sup>3,4</sup> Patients should be asked about the color, amount, frequency, and duration of bleeding and about any symptoms that may suggest a specific source of lower gastrointestinal bleeding. For example, abdominal pain with diarrhea may suggest inflammatory, ischemic, or infectious-type colitis, whereas altered bowel habits, iron-deficiency anemia, or unexplained weight loss may suggest colorectal cancer. Patients should also be questioned about any upper gastrointestinal symptoms, previous events of gastrointestinal bleeding, abdominal or vascular surgeries, peptic ulcer disease, inflammatory bowel disease, or abdominal–pelvic radiation therapy. Coexisting cardiopulmonary, renal, or hepatic conditions also require attention, because they are associated with an increased risk of poor outcome and may influence management.<sup>5</sup> Medications that could affect bleeding risk, such as nonsteroidal antiinflammatory drugs, antiplatelet agents, and anticoagulants, should be noted. Important components of the physical examination include vital signs (including postural changes), a cardiopulmonary examination,

and abdominal and digital rectal examinations. Anoscopy can be useful in patients with suspected hemorrhoidal bleeding ( $\leq 20\%$  of cases of acute lower gastrointestinal bleeding). However, if stigmata of recent hemorrhage are not clearly identified, endoscopic workup should be pursued. A complete blood count, coagulation studies, and blood typing and screening are recommended as initial laboratory tests. Levels of serum creatinine and blood urea nitrogen may also be helpful; an elevated ratio of blood urea nitrogen to creatinine ( $>30:1$ ) suggests an upper gastrointestinal source of bleeding.<sup>6</sup>

Risk factors for adverse outcomes (recurrent bleeding, need for intervention, or death) in patients presenting with presumed acute lower gastrointestinal bleeding include hypotension, tachycardia, ongoing hematochezia, an age of more than 60 years, a creatinine level of more than 1.7 mg per deciliter, and unstable or clinically significant coexisting conditions.<sup>7</sup> In general, the likelihood of an adverse outcome increases with the number of risk factors present.<sup>5,7</sup> However, risk-factor models based on these predictors are less well studied than models for upper gastrointestinal bleeding, were not developed to identify patients appropriate for outpatient management, and show only a limited ability to predict which patients will have poor outcomes and which will not have poor outcomes (area under the receiver-operating-characteristic curve,

0.72 to 0.79).<sup>5,7-12</sup> (For more on risk-factor models, see Table S1 in the Supplementary Appendix, available with the full text of this article at NEJM.org.)

#### INITIAL MANAGEMENT

Intravenous fluid resuscitation with crystalloids should be started on presentation.<sup>3,4,13</sup> A recent guideline for the management of acute lower gastrointestinal bleeding recommends a blood-transfusion approach that minimizes the administration of blood — similar to guideline recommendations for upper gastrointestinal bleeding.<sup>4,14</sup> Although randomized trials of transfusion thresholds have not included patients with lower gastrointestinal bleeding, these recommendations for the management of acute lower gastrointestinal bleeding are based on a large, randomized trial and a meta-analysis involving patients with acute upper gastrointestinal bleeding that showed both a decreased risk of rebleeding and a mortality benefit.<sup>15,16</sup> The guidelines recommend transfusion of packed red cells to maintain a hemoglobin level of more than 7 g per deciliter in most patients, with consideration of a transfusion threshold of 9 g per deciliter in patients with clinically significant coexisting illness (especially ischemic cardiovascular disease) or in the context of delayed therapeutic intervention.

#### INITIAL DIAGNOSTIC EVALUATION

##### Endoscopy

Colonoscopy is the initial procedure for nearly all patients presenting with acute lower gastrointestinal bleeding because it serves diagnostic and potentially therapeutic purposes.<sup>3,4</sup> Causes of acute lower gastrointestinal bleeding in adults are listed in Table 1. However, hematochezia in the context of hemodynamic instability (tachycardia and hypotension) may represent a brisk upper gastrointestinal bleeding event; therefore, upper endoscopy must also be considered in such patients and can be performed immediately before colonoscopy.<sup>3,4</sup> Colonoscopy should generally be performed within 24 hours after patient presentation, after hemodynamic resuscitation and adequate colon cleansing.<sup>4</sup> Observational studies have shown a higher frequency of definitive diagnoses and a shorter length of stay among patients with lower gastrointestinal

bleeding undergoing early colonoscopy (within 12 to 24 hours after presentation) than among those undergoing colonoscopy at a later time,<sup>18-20</sup> although two small, randomized trials comparing early with later colonoscopy did not show significant differences in length of stay or in rates of rebleeding or surgery.<sup>21,22</sup> Adequate preparation of the colon is important for endoscopic visualization, diagnosis, and treatment; preparation includes at least 4 liters of a polyethylene glycol solution or the equivalent, administered over a period of approximately 4 hours.<sup>3,4</sup> Colonoscopy or sigmoidoscopy without preparation should generally be avoided but can be considered in selected cases (e.g., suspected bleeding from the distal left colon), with careful cleaning and inspection of the colon during the procedure.<sup>4,23</sup> In patients with ongoing bleeding who cannot consume the preparation solution, the short-term placement of a nasogastric tube can be considered as long as the risk of aspiration is low. Patients should be without solid food for at least 8 hours before colonoscopy; clear fluids, including the colonoscopy preparation, are permitted up to 2 hours before colonoscopy.

**Table 1. Causes of Acute Lower Gastrointestinal Bleeding in Adults.\***

| Cause                          | Percentage of Cases |
|--------------------------------|---------------------|
| Diverticulosis                 | 30–65               |
| Ischemic colitis               | 5–20                |
| Hemorrhoids                    | 5–20                |
| Colorectal polyps or neoplasms | 2–15                |
| Angioectasias                  | 5–10                |
| Postpolypectomy bleeding       | 2–7                 |
| Inflammatory bowel disease     | 3–5                 |
| Infectious colitis             | 2–5                 |
| Stercoral ulceration           | 0–5                 |
| Colorectal varices             | 0–3                 |
| Radiation proctopathy          | 0–2                 |
| NSAID-induced colopathy        | 0–2                 |
| Dieulafoy's lesion             | Rare                |

\* NSAID denotes nonsteroidal antiinflammatory drug. Adapted from Strate and Naumann.<sup>17</sup>

### Radiographic Imaging

Noninvasive diagnostic imaging methods (e.g., multidetector computed tomographic [CT] angiography and radionuclide technetium-99m–labeled red-cell scintigraphy) may be performed before colonoscopy in patients with ongoing brisk bleeding and hemodynamic instability despite resuscitation efforts or in patients in whom colonoscopy was nondiagnostic or endoscopic hemostasis unsuccessful.<sup>4,24</sup> Although technetium-99m–labeled red-cell scintigraphy can detect bleeding rates as low as 0.1 ml per minute, its usefulness in acute lower gastrointestinal bleeding is debated. A retrospective study suggested that performance of scintigraphy before angiography was associated with a higher diagnostic yield of angiography than angiography without scintigraphy and may allow more selective contrast injection.<sup>25</sup> Other studies, however, have not confirmed these findings and have suggested greater usefulness of multidetector CT angiography.<sup>26</sup> Multidetector CT angiography has a bleeding detection rate threshold (0.3 ml per minute) similar to that of scintigraphy, is highly accurate at localizing the site of bleeding (nearly 100%), and can be used immediately before angiography to guide selective or superselective contrast injection and therapy during angiography.<sup>24,27</sup> Its primary drawback is the need for intravenous contrast material, with an associated risk of nephrotoxic effects, primarily in patients with preexisting renal insufficiency.<sup>24,27</sup> If scintigraphy or multidetector CT angiography is positive for bleeding, angiography should be performed as soon as possible to determine the precise location of bleeding and then deliver angiographic therapy, because active lower gastrointestinal bleeding is intermittent in nature (Fig. 1).<sup>24</sup>

### THERAPIES

#### Endoscopic Therapy

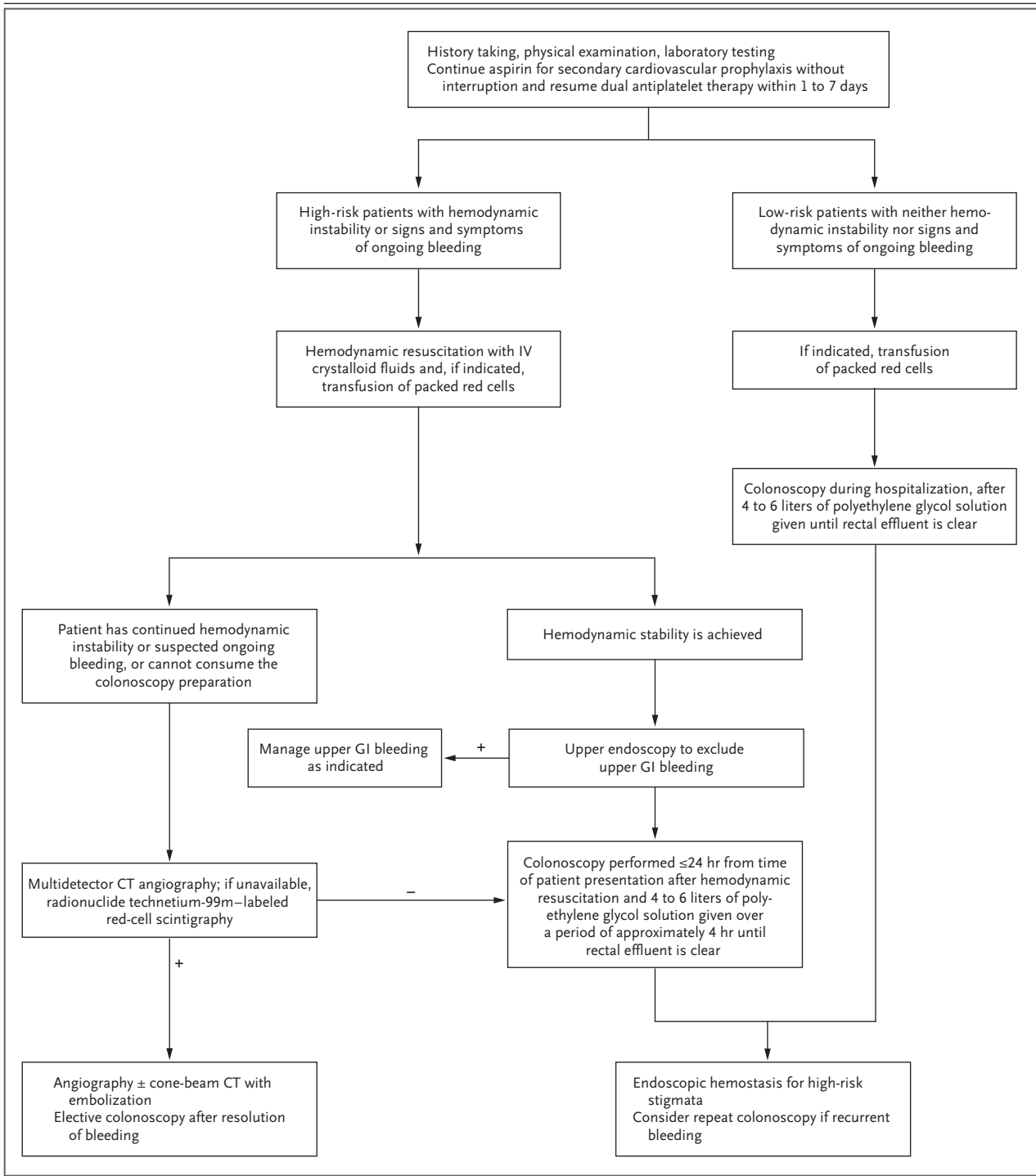
Endoscopic hemostasis methods for acute lower gastrointestinal bleeding include injection (usually diluted epinephrine), contact and noncontact thermal devices (bipolar electrocoagulation, heater probe, and argon plasma coagulation), and mechanical therapies (endoscopic clips and band ligation).<sup>3,4</sup> Diluted epinephrine injection (1:10,000 to 1:20,000 dilution) facilitates primary hemostasis of active bleeding but should be used in combination with a second method (e.g., mechanical

or contact thermal therapy) to achieve definitive hemostasis.<sup>3,4</sup> Randomized trials are lacking to assess the effects of endoscopic hemostasis for acute lower gastrointestinal bleeding. The choice of hemostasis method is generally guided by the cause and location of bleeding, the ability to access the site, and operator experience.

Diverticulosis, angioectasias, and postpolypectomy bleeding are the sources of lower gastrointestinal bleeding that are most likely to benefit from endoscopic hemostasis.<sup>3,4</sup> Evidence of the efficacy and safety of endoscopic hemostasis in lower gastrointestinal bleeding is derived largely from observational studies and case series of diverticular hemorrhage.<sup>17-19,28</sup> A comprehensive review showed successful endoscopic hemostasis in 92% of patients, early rebleeding in 8%, and late rebleeding in 12%.<sup>17</sup> Adverse events (including perforation, worsened bleeding, and congestive heart failure) occurred in 0.3 to 1.3% of patients.<sup>17</sup> Guidelines recommend that diverticular bleeding be treated endoscopically if stigmata of recent hemorrhage are present (e.g., active bleeding, nonbleeding visible vessel, or adherent clot) at colonoscopy (Fig. 2A).<sup>3,4</sup> Mechanical therapy, with the use of endoscopic clips, is preferred for diverticular bleeding because clips reduce the theoretical risk of transmural colonic injury associated with contact thermal therapy (Fig. 2B). Technological improvements allowing full rotation have made clips easier to use.<sup>28</sup>

Colonic angioectasias, including radiation proctopathy, are common in the elderly, and although they usually manifest as mild overt rectal bleeding, they can manifest as severe hematochezia, especially in patients who are taking antithrombotic agents.<sup>29</sup> Argon plasma coagulation therapy is considered the treatment of choice for these lesions on the basis of ease of use, safety profile, and observations of increased hemoglobin levels and reduced blood-transfusion requirements associated with its use.<sup>3,4,30</sup>

Endoscopic approaches to treating postpolypectomy bleeding include mechanical devices (clipping or band ligation) and contact thermal coagulation with or without dilute epinephrine injection.<sup>3,4</sup> The use of clips may be preferred in order to limit tissue injury.<sup>4</sup> After endoscopic treatment, a tattoo or clip (if not already used for hemostasis) can be placed adjacent to any culprit lesion to assist in relocalization should rebleeding occur.<sup>4</sup>



In patients with evidence of recurrent lower gastrointestinal bleeding, repeat colonoscopy (with endoscopic hemostasis, if indicated) should be considered.<sup>3,4</sup> Acute lower gastrointestinal bleeding caused by ischemic colitis, inflammatory ulcerative colitis, or colorectal neoplasms is generally not amenable to durable endoscopic hemostasis and is usually treated

**Figure 1 (facing page). Management Strategy for Acute Lower Gastrointestinal Bleeding.**

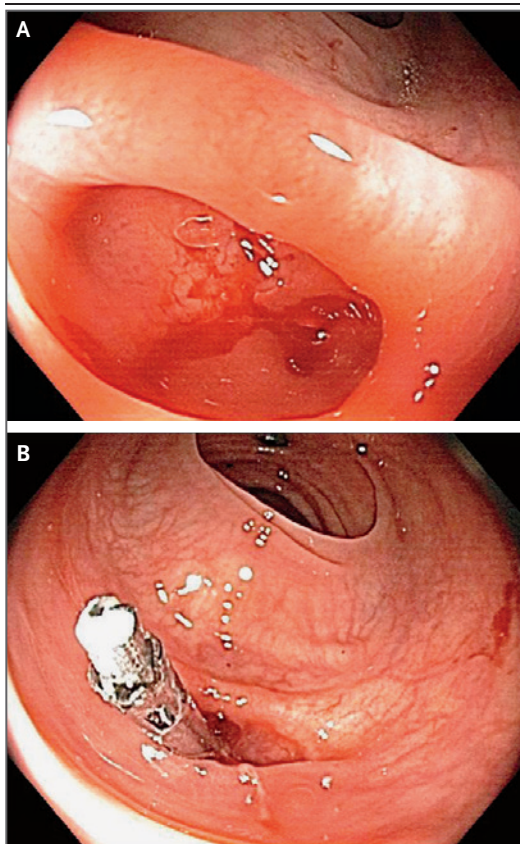
Aspirin used for primary cardiovascular prophylaxis should be avoided in patients with lower gastrointestinal bleeding. Aspirin used for secondary cardiovascular prophylaxis should be continued without interruption. The second, nonaspirin agent in dual antiplatelet therapy should be stopped temporarily, with resumption 1 to 7 days after the cessation of bleeding. Dual antiplatelet therapy should not be discontinued in the 30 days after coronary stenting or in the 90 days after an acute coronary syndrome. Risk factors associated with a poor outcome of lower gastrointestinal bleeding are listed in Table S1 in the Supplementary Appendix. Transfusion of packed red cells is recommended to maintain a hemoglobin level of more than 7 g per deciliter; consider a transfusion threshold of 9 g per deciliter in patients with clinically significant coexisting conditions (especially ischemic cardiovascular disease) or if a delay in intervention is expected. A nasogastric tube may be considered to facilitate colonoscopy preparation in patients who cannot consume the colonoscopy preparation solution and are at low risk for aspiration. A prokinetic antiemetic agent (e.g., metoclopramide) may also be considered, but the potential for associated adverse events (e.g., tardive dyskinesia) should be understood. A plus sign (+) indicates a positive test for bleeding, and a minus sign (-) indicates a negative test for bleeding. CT denotes computed tomography, GI gastrointestinal, and IV intravenous.

with supportive medical care, surgical care, or both.

**Angiography and Endovascular Therapy**

Angiography allows both bleeding-site localization (Fig. 3A) and therapeutic intervention.<sup>24,31,32</sup> However, angiography may be negative if the bleeding is slow (<0.5 ml per minute) or intermittent. Use of provocative angiography (e.g., involving heparin, nitroglycerin, urokinase, or tissue plasminogen activator) may increase the likelihood of identifying a bleeding site<sup>33</sup> but confers a risk of uncontrolled bleeding, and therefore this procedure should be performed only at selected experienced centers.

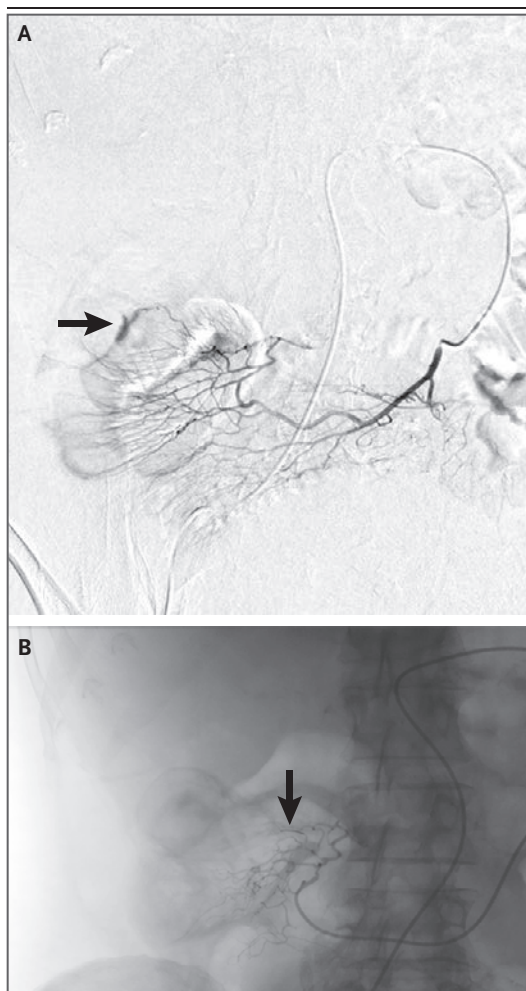
The goal of selective transcatheter endovascular therapy is to decrease arterial perfusion to the bleeding site, which facilitates healing of the injured vessel. Microcatheters (1.9 to 3.0 French) enable superselective embolization of arteries less than 1 mm in diameter, with the use of microcoils (Fig. 3B), absorbable gelatin sponges, cyanoacrylate glue, or ethylene vinyl or polyvinyl



**Figure 2. Diverticular Hemorrhage as Seen on Colonoscopy.**

Panel A shows active bleeding from a diverticulum, and Panel B shows postendoscopic clip placement leading to cessation of bleeding.

alcohol. Case series show high rates of successful embolization (no further contrast extravasation) in lower gastrointestinal bleeding (73 to 100%); rates of clinical success (cessation of bleeding) range from 63 to 96%, with rebleeding rates of 11 to 50%.<sup>24</sup> In the absence of studies that directly compare the various embolic agents, the choice of agent is usually based on operator discretion and availability. Angiography with transcatheter embolization carries a risk of bowel ischemia (incidence, 1 to 4%) and should be reserved for patients with brisk, ongoing bleeding that is not amenable to or not effectively treated by endoscopic management.<sup>24</sup> Risk factors for bowel ischemia include particle embolization, an inability for superselective catheterization to be performed, and embolization of distal arteries more than 1 mm in diameter or



**Figure 3. Angiographic Diagnosis and Therapy of Acute Colonic Bleeding.**

Panel A shows angiographic evidence of active bleeding from the right colon (the arrow points to the site of active bleeding). Panel B shows the cessation of bleeding after superselective microcoil embolization (the arrow points to a single coil). Images courtesy of Dr. Eli Atar, Diagnostic Imaging Department, Rabin Medical Center, Petah Tikva, Israel.

of arteries located proximal to the mesentery. (For details on procedures for the evaluation and treatment of acute lower gastrointestinal bleeding, see Table 2.)

#### *Surgery*

Surgical consultation is indicated in patients with ongoing lower gastrointestinal bleeding in whom endoscopic and radiographic treatment has failed.<sup>4</sup> Localization of the bleeding lesion

before surgical resection is critical to prevent the need for subtotal colectomy and to prevent recurrent bleeding after surgery, owing to a missed or incorrectly localized lesion. If the upper bowel and small bowel have been ruled out as the source of bleeding but the colonic location of bleeding cannot be identified, a subtotal colectomy may be appropriate. However, subtotal colectomy is associated with higher morbidity and mortality than segmental resection.<sup>34,35</sup>

#### **ANTIPLATELET AGENTS AND ACUTE LOWER GASTROINTESTINAL BLEEDING**

Antiplatelet agents increase the risk of gastrointestinal bleeding; the risk of lower gastrointestinal bleeding is approximately three times that of upper gastrointestinal bleeding.<sup>36,37</sup> Data on resuming aspirin in the context of gastrointestinal bleeding are derived almost exclusively from studies of peptic-ulcer bleeding. In a relatively small, randomized trial examining the continuation of low-dose aspirin after endoscopic therapy for peptic-ulcer bleeding among persons with known cardiovascular disease, the risk of death was significantly higher among those who discontinued aspirin than among those who continued; rates of rebleeding did not differ significantly between the groups.<sup>38</sup> A retrospective cohort study involving patients with lower gastrointestinal bleeding showed that those who continued aspirin after the bleeding event had significantly higher rates of recurrent lower gastrointestinal bleeding over the ensuing 5 years than nonusers of aspirin (18.9% vs. 6.9%) but significantly lower rates of serious cardiovascular events and death.<sup>39</sup> To minimize the risk of cardiovascular events, aspirin for secondary prophylaxis should not be interrupted in patients with acute lower gastrointestinal bleeding.<sup>4,39</sup> However, low-dose aspirin for primary prophylaxis has been shown to result in only a limited reduction in the absolute risk of serious cardiovascular events or death and should generally be avoided in persons with a history of lower gastrointestinal bleeding.<sup>40</sup>

Data are lacking to guide the care of patients who have a lower gastrointestinal bleeding event while receiving dual antiplatelet therapy.<sup>41</sup> Patients who have undergone stenting in the previous 30 days or who have had an acute coronary syndrome in the previous 90 days are at particularly

**Table 2. Procedures for the Evaluation and Treatment of Acute Lower Gastrointestinal Bleeding.\***

| Procedure                         | Advantages  | Disadvantages   |
|-----------------------------------|---|---|
| <b>Diagnostic and therapeutic</b> |   |   |
| Colonoscopy                       | Excellent safety profile; high diagnostic and therapeutic yield, so can provide a definitive diagnosis even if active bleeding has stopped†   | Large-volume, rapid preparation of the colon required before the procedure  |
| Angiography                       | Appropriate for patients with brisk bleeding whose condition cannot be hemodynamically stabilized for colonoscopy or those who have ongoing or recurrent brisk bleeding after colonoscopy; diagnosis can be made and treatment can be implemented for any source of gastrointestinal bleeding | Relies on brisk, active bleeding at the time of the examination; higher rate of adverse events than that with colonoscopy; diagnosis often must be confirmed with colonoscopy   |
| <b>Diagnostic only</b>            |   |   |
| Multidetector CT angiography      | Sensitive to low rates of active bleeding; highly accurate in localizing the bleeding source; provides an anatomical “roadmap” for therapeutic interventions; widely available  | Relies on active bleeding at the time of the examination; diagnostic only, not therapeutic; involves exposure to intravenous contrast agent, which may pose a particular risk to patients with existing chronic renal insufficiency                                     |
| Radionuclide scintigraphy         | Sensitive to low rates of active bleeding; may improve the diagnostic yield of angiography and guide selective contrast injection   | Relies on active bleeding at the time of the examination; not as widely available as multidetector CT angiography; less accurate in localizing the bleeding source than other diagnostic methods; diagnostic only, not therapeutic; may delay therapeutic interventions |

\* CT denotes computed tomography.

† Because a finding of major stigmata of hemorrhage on a single diverticulum at the time of colonoscopy is uncommon, the diagnosis of diverticular bleeding is often considered presumptive rather than definitive. The diagnosis of presumptive diverticular bleeding requires only the presence of colonic diverticula, with no other obvious endoscopic cause of lower gastrointestinal bleeding identified.

high risk for myocardial infarction and death after discontinuation of dual antiplatelet therapy and thus are generally advised to continue taking both medications.<sup>42</sup> In patients who underwent coronary stenting or had a coronary syndrome less recently, discontinuation of the second antiplatelet agent is recommended for 1 to 7 days, because discontinuation of the second, nonaspirin antiplatelet agent appears to be associated with relatively low risk as long as aspirin therapy is not interrupted.<sup>43</sup>

#### AREAS OF UNCERTAINTY

Randomized trials are needed to better delineate the most effective timing of colonoscopy, the role of colonoscopy versus radiography as the initial diagnostic method, the choice among radiographic imaging studies, and the efficacy and safety of endoscopic hemostasis treatments (including topical powders, band ligation, over-the-scope clips, and Doppler ultrasonography as an adjunct to endoscopic hemostasis) in lower gas-

trointestinal bleeding.<sup>44-47</sup> The efficacy of cone-beam CT technology as an adjunctive diagnostic method in selective angiography and the embolic agent of choice in endovascular therapy are unclear.<sup>48</sup> In addition, better risk-stratification tools are needed to improve the triage of patients with lower gastrointestinal bleeding.

#### GUIDELINES

Guidelines for the evaluation and management of acute lower gastrointestinal bleeding and severe hematochezia have been published by U.S. professional societies of gastroenterologists and radiologists.<sup>3,4,24</sup> The recommendations in this article are generally concordant with these guidelines.

#### CONCLUSIONS AND RECOMMENDATIONS

Diverticular hemorrhage is the most likely cause of the acute lower gastrointestinal bleeding in the patient described in the vignette. This patient



is at increased risk for a poor outcome owing to her advanced age, coexisting conditions, hemodynamic instability at presentation, fresh blood on rectal examination, and use of dual antiplatelet therapy. Volume resuscitation with crystalloid fluids should be initiated immediately. The hemoglobin level should be reevaluated after hemodynamic resuscitation to assess the need for transfusion. If hemodynamic stability is achieved, the patient should undergo colonoscopy within 24 hours after presentation, after adequate colon preparation. Given her initial hemodynamic instability and use of dual antiplatelet therapy, upper endoscopy should be performed immediately before colonoscopy to rule out an upper gastrointestinal source of bleeding. Endoscopic hemostasis therapy may be applied if a definitive bleeding lesion is identified. If the patient has ongoing bleeding or an inadequate hemodynamic

response to fluid resuscitation and cannot undergo colonoscopy, we would perform radiographic evaluation, initially using multidetector CT angiography and then angiography and embolization if indicated. Her low-dose aspirin should be continued without interruption. Because the patient's coronary stent was placed more than 30 days ago, we would stop clopidogrel temporarily and resume its use 1 to 7 days after the cessation of bleeding.

Dr. Gralnek reports receiving fees for serving on an advisory board from MOTUS GI, receiving consulting fees from EndoChoice, MOTUS GI, and GI-View, receiving honoraria from EndoChoice, MOTUS GI, Boston Scientific, Takeda Pharmaceuticals, and GI-View, receiving grant support from MOTUS GI and EndoAid, receiving an endoscopy workstation from EndoChoice, serving as an unpaid consultant to EndoAid, and serving on a data and safety monitoring board for Intec Pharma. No other potential conflict of interest relevant to this article was reported.

Disclosure forms provided by the authors are available with the full text of this article at NEJM.org.

#### REFERENCES

1. Peery AF, Crockett SD, Barritt AS, et al. Burden of gastrointestinal, liver, and pancreatic diseases in the United States. *Gastroenterology* 2015;149(7):1731-1741.e3.
2. Strate LL, Ayanian JZ, Kotler G, Syngal S. Risk factors for mortality in lower intestinal bleeding. *Clin Gastroenterol Hepatol* 2008;6:1004-10.
3. Pasha SF, Shergill A, Acosta RD, et al. The role of endoscopy in the patient with lower GI bleeding. *Gastrointest Endosc* 2014;79:875-85.
4. Strate LL, Gralnek IM. ACG clinical guideline: management of patients with acute lower gastrointestinal bleeding. *Am J Gastroenterol* 2016;111:459-74.
5. Newman J, Fitzgerald JE, Gupta S, von Room AC, Sigurdsson HH, Allen-Mersh TG. Outcome predictors in acute surgical admissions for lower gastrointestinal bleeding. *Colorectal Dis* 2012;14:1020-6.
6. Srygley FD, Gerardo CJ, Tran T, Fisher DA. Does this patient have a severe upper gastrointestinal bleed? *JAMA* 2012;307:1072-9.
7. Aoki T, Nagata N, Shimbo T, et al. Development and validation of a risk scoring system for severe acute lower gastrointestinal bleeding. *Clin Gastroenterol Hepatol* 2016;14(11):1562-1570.e2.
8. Kollef MH, O'Brien JD, Zuckerman GR, Shannon W. BLEED: a classification tool to predict outcomes in patients with acute upper and lower gastrointestinal hemorrhage. *Crit Care Med* 1997;25:1125-32.
9. Das A, Ben-Menachem T, Cooper GS, et al. Prediction of outcome in acute lower-gastrointestinal haemorrhage based on an artificial neural network: internal and external validation of a predictive model. *Lancet* 2003;362:1261-6.
10. Strate LL, Orav EJ, Syngal S. Early predictors of severity in acute lower intestinal tract bleeding. *Arch Intern Med* 2003;163:838-43.
11. Strate LL, Saltzman JR, Ookubo R, Mutinga ML, Syngal S. Validation of a clinical prediction rule for severe acute lower intestinal bleeding. *Am J Gastroenterol* 2005;100:1821-7.
12. Velayos FS, Williamson A, Sousa KH, et al. Early predictors of severe lower gastrointestinal bleeding and adverse outcomes: a prospective study. *Clin Gastroenterol Hepatol* 2004;2:485-90.
13. Baradarian R, Ramdhaney S, Chapalamadugu R, et al. Early intensive resuscitation of patients with upper gastrointestinal bleeding decreases mortality. *Am J Gastroenterol* 2004;99:619-22.
14. Gralnek IM, Dumonceau JM, Kuipers EJ, et al. Diagnosis and management of nonvariceal upper gastrointestinal hemorrhage: European Society of Gastrointestinal Endoscopy (ESGE) guideline. *Endoscopy* 2015;47:a1-a46.
15. Villanueva C, Colomo A, Bosch A. Transfusion for acute upper gastrointestinal bleeding. *N Engl J Med* 2013;368:1362-3.
16. Wang J, Bao YX, Bai M, Zhang YG, Xu WD, Qi XS. Restrictive vs liberal transfusion for upper gastrointestinal bleeding: a meta-analysis of randomized controlled trials. *World J Gastroenterol* 2013;19:6919-27.
17. Strate LL, Naumann CR. The role of colonoscopy and radiological procedures in the management of acute lower intestinal bleeding. *Clin Gastroenterol Hepatol* 2010;8:333-43.
18. Jensen DM, Machicado GA. Diagnosis and treatment of severe hematochezia: the role of urgent colonoscopy after purge. *Gastroenterology* 1988;95:1569-74.
19. Jensen DM, Machicado GA, Jutabha R, Kovacs TOG. Urgent colonoscopy for the diagnosis and treatment of severe diverticular hemorrhage. *N Engl J Med* 2000;342:78-82.
20. Strate LL, Syngal S. Timing of colonoscopy: impact on length of hospital stay in patients with acute lower intestinal bleeding. *Am J Gastroenterol* 2003;98:317-22.
21. Green BT, Rockey DC, Portwood G, et al. Urgent colonoscopy for evaluation and management of acute lower gastrointestinal hemorrhage: a randomized controlled trial. *Am J Gastroenterol* 2005;100:2395-402.
22. Laine L, Shah A. Randomized trial of urgent vs. elective colonoscopy in patients hospitalized with lower GI bleeding. *Am J Gastroenterol* 2010;105:2636-42.
23. Lhewa DY, Strate LL. Pros and cons of colonoscopy in management of acute lower gastrointestinal bleeding. *World J Gastroenterol* 2012;18:1185-90.
24. American College of Radiology (ACR) Appropriateness Criteria: radiologic management of lower gastrointestinal tract bleeding (updated 2014) (<https://acsearch.acr.org/docs/69457/Narrative/>).
25. Gunderman R, Leef J, Ong K, Reba R, Metz C. Scintigraphic screening prior to

- visceral arteriography in acute lower gastrointestinal bleeding. *J Nucl Med* 1998; 39:1081-3.
26. Zink SI, Ohki SK, Stein B, et al. Non-invasive evaluation of active lower gastrointestinal bleeding: comparison between contrast-enhanced MDCT and 99mTc-labeled RBC scintigraphy. *AJR Am J Roentgenol* 2008;191:1107-14.
27. Jacovides CL, Nadolski G, Allen SR, et al. Arteriography for lower gastrointestinal hemorrhage: role of preceding abdominal computed tomographic angiogram in diagnosis and treatment of diverticular bleeding. *JAMA Surg* 2015; 150:650-6.
28. Kaltenbach T, Watson R, Shah J, et al. Colonoscopy with clipping is useful in the diagnosis and treatment of diverticular bleeding. *Clin Gastroenterol Hepatol* 2012; 10:131-7.
29. Diggs NG, Holub JL, Lieberman DA, Eisen GM, Strate LL. Factors that contribute to blood loss in patients with colonic angiodysplasia from a population-based study. *Clin Gastroenterol Hepatol* 2011;9: 415-20.
30. Olmos JA, Marcolongo M, Pogorelsky V, Herrera L, Tobal F, Dávalos JR. Long-term outcome of argon plasma ablation therapy for bleeding in 100 consecutive patients with colonic angiodysplasia. *Dis Colon Rectum* 2006;49:1507-16.
31. Koh DC, Luchtefeld MA, Kim DG, et al. Efficacy of transarterial embolization as definitive treatment in lower gastrointestinal bleeding. *Colorectal Dis* 2009;11:53-9.
32. Yi WS, Garg G, Sava JA. Localization and definitive control of lower gastrointestinal bleeding with angiography and embolization. *Am Surg* 2013;79:375-80.
33. Kim CY, Suhocki PV, Miller MJ Jr, Khan M, Janus G, Smith TP. Provocative mesenteric angiography for lower gastrointestinal hemorrhage: results from a single-institution study. *J Vasc Interv Radiol* 2010;21:477-83.
34. Farner R, Lichliter W, Kuhn J, Fisher T. Total colectomy versus limited colonic resection for acute lower gastrointestinal bleeding. *Am J Surg* 1999;178:587-91.
35. Bender JS, Wienczek RG, Bouwman DL. Morbidity and mortality following total abdominal colectomy for massive lower gastrointestinal bleeding. *Am Surg* 1991; 57:536-41.
36. Casado Arroyo R, Polo-Tomas M, Roncalés MP, Scheiman J, Lanás A. Lower GI bleeding is more common than upper among patients on dual antiplatelet therapy: long-term follow-up of a cohort of patients commonly using PPI co-therapy. *Heart* 2012;98:718-23.
37. Abraham NS, Hartman C, Richardson P, Castillo D, Street RL Jr, Naik AD. Risk of lower and upper gastrointestinal bleeding, transfusions, and hospitalizations with complex antithrombotic therapy in elderly patients. *Circulation* 2013;128: 1869-77.
38. Sung JJ, Lau JY, Ching JY, et al. Continuation of low-dose aspirin therapy in peptic ulcer bleeding: a randomized trial. *Ann Intern Med* 2010;152:1-9.
39. Chan FKL, Leung Ki EL, Wong GLH, et al. Risks of bleeding recurrence and cardiovascular events with continued aspirin use after lower gastrointestinal hemorrhage. *Gastroenterology* 2016;151: 271-7.
40. Baigent C, Blackwell L, Collins R, et al. Aspirin in the primary and secondary prevention of vascular disease: collaborative meta-analysis of individual participant data from randomised trials. *Lancet* 2009;373: 1849-60.
41. Bhatt DL, Scheiman J, Abraham NS, et al. ACCF/ACG/AHA 2008 expert consensus document on reducing the gastrointestinal risks of antiplatelet therapy and NSAID use. *Am J Gastroenterol* 2008;103: 2890-907.
42. Ho PM, Peterson ED, Wang L, et al. Incidence of death and acute myocardial infarction associated with stopping clopidogrel after acute coronary syndrome. *JAMA* 2008;299:532-9.
43. Eisenberg MJ, Richard PR, Libersan D, Filion KB. Safety of short-term discontinuation of antiplatelet therapy in patients with drug-eluting stents. *Circulation* 2009; 119:1634-42.
44. Barkun AN, Moosavi S, Martel M. Topical hemostatic agents: a systematic review with particular emphasis on endoscopic application in GI bleeding. *Gastrointest Endosc* 2013;77:692-700.
45. Ishii N, Setoyama T, Deshpande GA, et al. Endoscopic band ligation for colonic diverticular hemorrhage. *Gastrointest Endosc* 2012;75:382-7.
46. Manta R, Galloro G, Mangiavillano B, et al. Over-the-scope clip (OTSC) represents an effective endoscopic treatment for acute GI bleeding after failure of conventional techniques. *Surg Endosc* 2013; 27:3162-4.
47. Jensen DM, Ohning GV, Kovacs TO, et al. Natural history of definitive diverticular hemorrhage based on stigmata of recent hemorrhage and colonoscopic Doppler blood flow monitoring for risk stratification and definitive hemostasis. *Gastrointest Endosc* 2016;83:416-23.
48. Ierardi AM, Urbano J, De Marchi G, et al. New advances in lower gastrointestinal bleeding management with embolotherapy. *Br J Radiol* 2016 February 4 (Epub ahead of print).

Copyright © 2017 Massachusetts Medical Society.

**NEJM CLINICAL PRACTICE CENTER**

Explore a new page designed specifically for practicing clinicians, the NEJM Clinical Practice Center, at [NEJM.org/clinical-practice-center](http://NEJM.org/clinical-practice-center). Find practice-changing research, reviews from our Clinical Practice series, a curated collection of clinical cases, and interactive features designed to hone your diagnostic skills.