

# Presentation and Management of Common Post-Weight Loss Surgery Problems in the Emergency Department

**Eric D. Edwards, MD**

**Brian P. Jacob, MD**

**Michel Gagner, MD**

**Alfons Pomp, MD**

From the Department of Surgery, Weill Medical College of Cornell University, New York–Presbyterian Hospital, New York, NY.

Morbid obesity is an epidemic in this country. An increasing number of patients are undergoing weight loss surgery in an effort to combat the negative physical and psychological impact of morbid obesity. Fueling the increasing interest in surgical treatment of morbid obesity has been the development of new laparoscopic techniques. There are several surgical approaches to morbid obesity, and each has its own unique set of risks and potential complications. As more patients have weight loss surgery, clinicians working in the emergency department will frequently encounter complications of these procedures. To ensure timely diagnosis and optimal care, clinicians should be familiar with the standard weight loss approaches and the potential complications of these interventions.

[Ann Emerg Med. 2006;47:160-166.]

0196-0644/\$-see front matter

Copyright © 2006 by the American College of Emergency Physicians.

doi:10.1016/j.annemergmed.2005.06.447

## INTRODUCTION

The prevalence of obesity has increased in the United States from 13.3% to 30% from 1960 to 2000.<sup>1</sup> Nearly two thirds of Americans are considered overweight (body mass index  $>25$  kg/m<sup>2</sup>), and half of those categorized as overweight are considered obese (body mass index  $>30$  kg/m<sup>2</sup>).<sup>2</sup> The increasing prevalence of obesity has been accompanied by resurgence in bariatric surgery. In 2001, approximately 30,000 weight loss procedures were performed. That number had increased to approximately 60,000 in 2003. This recent increase in bariatric surgery has also been fueled in part by the application of laparoscopic techniques in the treatment of morbid obesity.<sup>3,4</sup>

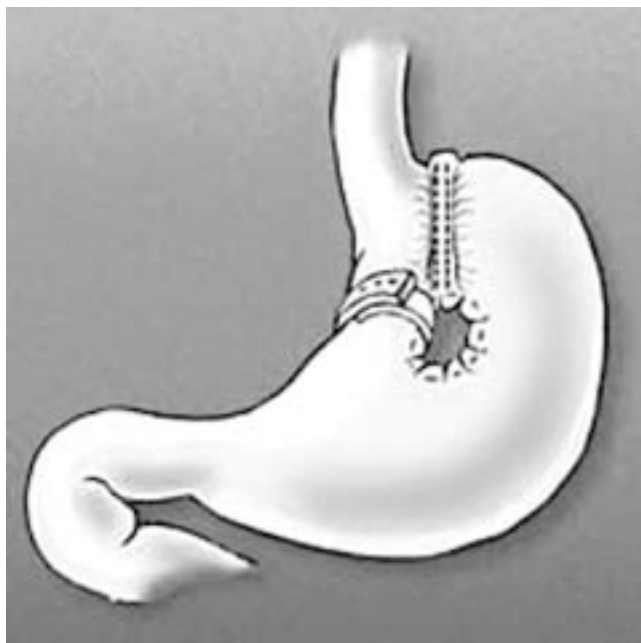
There are many surgical approaches to achieving excess weight loss in the morbidly obese patient. The risks of any intra-abdominal surgical procedure include surgical site infection, bleeding, and even death. Unique to providing care to the morbidly obese is that they often do not manifest signs and symptoms of significant intra-abdominal pathology. Signs of peritonitis can be masked by the large amount of intra-abdominal fat. Further, morbidly obese individuals lack the physiologic reserve of ideal-weight patients, which can lead to rapid clinical deterioration. With any of the surgical approaches to weight loss, there exist unique risks to the patients and commonly encountered specific postoperative complications. Some of these complications may present in the emergency department (ED) and require the physician to have a basic understanding of both the procedure that was performed and subsequent problems.

This review will present the basics of each weight loss procedure, as well as the common complications of each procedure and the management of these problems.

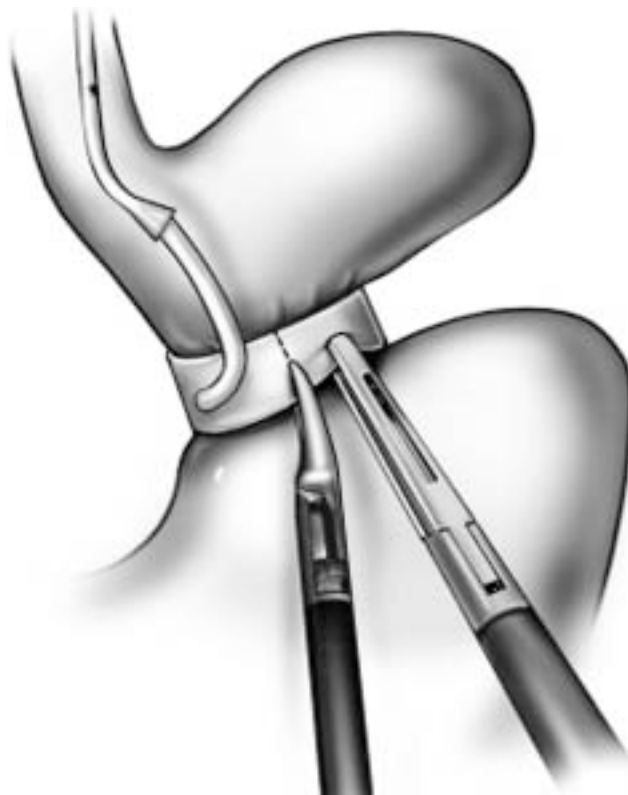## Vertical Banded Gastroplasty

Vertical banded gastroplasty is a purely restrictive procedure. A small pouch is made along the lesser curvature of the stomach using surgical staplers. A nonadjustable band then constricts the outlet from the pouch (Figure 1). This procedure relies on reduced food intake to achieve weight loss. Patients who have undergone vertical banded gastroplasty are usually not at risk for the metabolic complications seen with the Roux-en-Y and biliopancreatic diversion. They are, however, at risk for complications of intra-abdominal surgery such as surgical site infection and bowel obstruction.

Initial reports about the success of the vertical banded gastroplasty in producing weight loss were encouraging, but long-term follow-up of patients has revealed that it is not an extremely effective form of weight loss surgery. Overall, patients tend to lose approximately 50% of excess weight during the first 2 years postprocedure. After that, a significant proportion of patients begin to gain weight.<sup>5,6</sup> A relatively large number of patients who have undergone vertical banded gastroplasty eventually undergo some other form of weight loss surgery, usually a Roux-en-Y.<sup>7</sup> It is thought that patients who undergo a vertical banded gastroplasty circumvent this restrictive procedure by eating soft, high-calorie foods. The vertical banded gastroplasty is mostly of historical interest in that the restrictive procedure of choice is now laparoscopic adjustable gastric banding.



**Figure 1.** Vertical banded gastroplasty.



**Figure 2.** LAP-BAND.

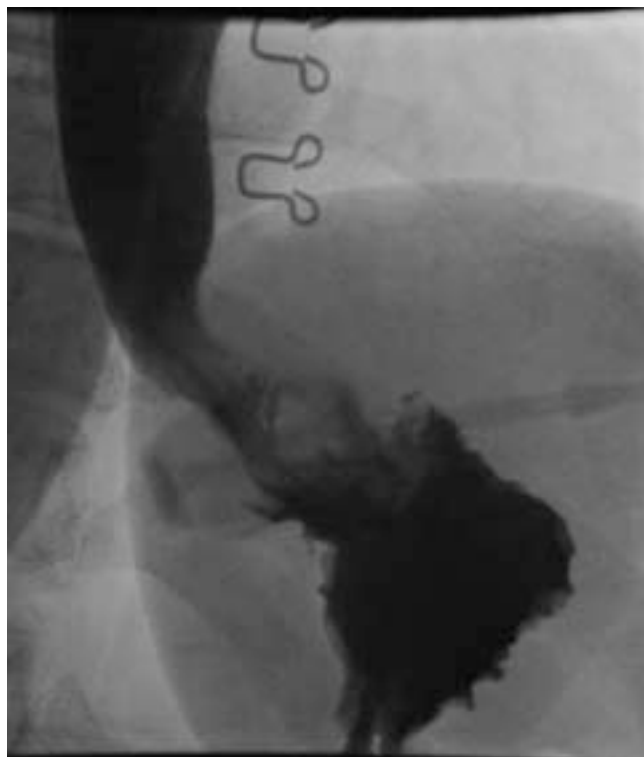
### Laparoscopic Adjustable Gastric Banding

Laparoscopic adjustable gastric banding is a relatively new technique used in the surgical treatment of morbid obesity. There is only 1 US Food and Drug Administration–approved (June 2001) device on the market, the LAP-BAND (INAMED Health, Santa Barbara, CA). It consists of an adjustable silastic band that is positioned around the upper portion of the stomach. The band is connected to a port that is implanted under the skin (Figure 2). The port is similar to those used for vascular access and allows the band to be tightened or loosened, depending on clinical need. Several purported advantages over the vertical banded gastroplasty include the absence of surgical stapling of the stomach and thus a decreased risk of perforation or fistula formation, the ability to regulate degree of restriction postoperatively, and the relative simple potential for reversibility.

Compared to Roux-en-Y, the laparoscopic adjustable gastric banding produces less excess weight loss, 74.6% versus 40.4% at 18 months.<sup>8</sup> Data about long-term results with this technique showing sustained weight loss in North America are still pending. There is a significant incidence of mechanical problems, including breakage, infection, and even erosion of the band into the gastrointestinal tract. Nonetheless, the cumulative operative risks for the laparoscopic adjustable gastric band appear to be less than that for gastric bypass. The laparoscopic adjustable gastric banding often appeals to patients primarily because initial indications are that it is effective and it does not involve major intra-abdominal surgery. Despite the perception that laparoscopic adjustable gastric banding is not a major operation, the procedure does carry risk of significant complications.

Patients undergoing this procedure are typically discharged home on postoperative day 1. In many centers, patients are sent home on the same day as the procedure. The band is not inflated in the immediate postoperative period, because the presence of the band, combined with postsurgical edema, creates some degree of restriction. A well-positioned band is one that is at a 30- to 45-degree angle according to plain radiographs from the horizontal at the gastroesophageal junction (Figure 3). In the immediate postoperative period, patients may present with vomiting as a result of gastroesophageal obstruction caused by edema or proximal movement of the band.<sup>9</sup> Concerns about position of the band can be addressed with swallow studies done under fluoroscopy. Proximal movement of the band must be treated surgically. Refinement of surgical technique has led to a decrease in this complication.<sup>10</sup> A patient with a well-positioned band who is in the early postoperative period may be treated conservatively with intravenous hydration until the edema resolves.

Migration or “slippage” may occur chronically and result in gastric dilatation with associated food intolerance.<sup>11</sup> Migration refers to the movement of some portion of the stomach originally located below the band to a position above the band (Figure 4). This process may also occur acutely long after the original surgery and may quickly lead to gastric necrosis and perforation. Patients who present to the ED with a clinical diagnosis consistent with acute gastroesophageal obstruction should have their bands deflated as quickly as possible. This

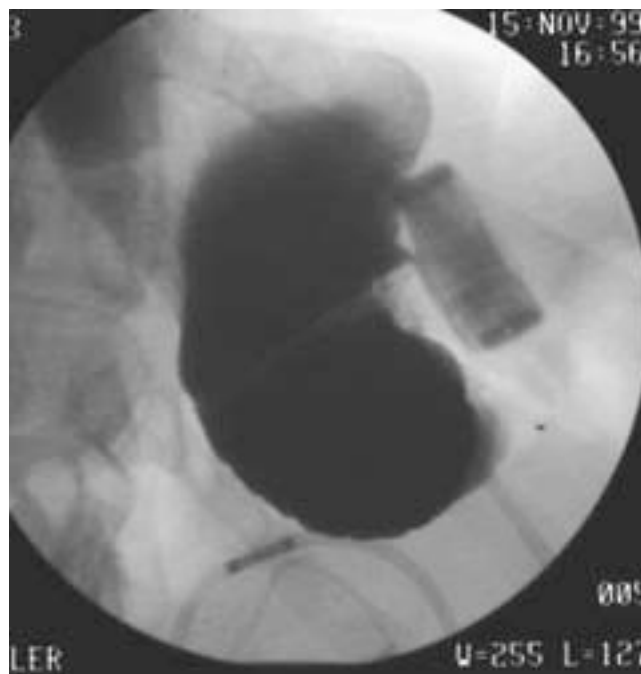

**Figure 3.** Normally positioned LAP-BAND.

intervention may prevent acute obstruction from progressing to frank perforation. The band can be deflated by infiltrating the overlying skin with lidocaine, stabilizing the port between 2 fingers, and then accessing the port with a large-bore needle. The standard LAP-BAND reservoir can hold up to 5 mL of saline. Occasionally, because of the patient's body habitus, it may be necessary to access the port under fluoroscopic guidance (Figure 5). After the band is deflated, a water-soluble contrast swallow study should be obtained. Prompt surgical consultation is also warranted.

Another late complication of laparoscopic adjustable gastric banding is gastric erosion. In one large study, gastric erosion occurred in 6.8% of patients.<sup>12</sup> In this situation, the band erodes through the full thickness of the stomach wall. Patients may present with evidence of intra-abdominal sepsis caused by perforation with or without abscess. Patients may develop gastrocutaneous fistulas. Alternatively, they may present with "late" infection at the port site.<sup>13</sup> Treatment for this problem consists of surgical removal and repair of the gastric perforation.

Finally, patients may develop complications associated with the subcutaneous port and the tubing connecting it to the band. Patients may develop port-site infection, tubing disconnection, leak of the reservoir, and skin ulceration.<sup>14</sup> Patients who have undergone laparoscopic adjustable gastric banding and present complaining of acute-onset abdominal pain may have separation of the tubing from the port,<sup>15</sup> which can be diagnosed with either plain radiographs or computed tomography (CT) scanning of the abdomen and pelvis. Tubing



**Figure 4.** LAP-BAND migration.

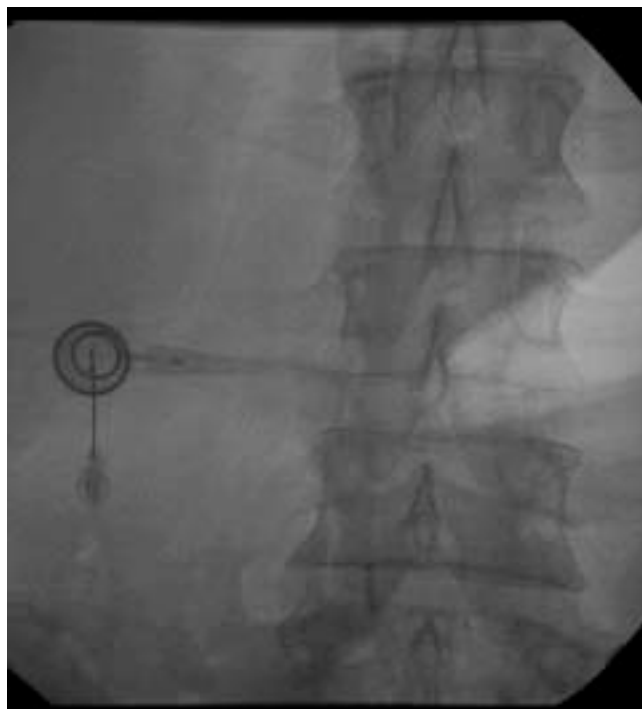dislodgement requires surgical intervention. Infection of the port site, as evidenced by erythema, tenderness, or drainage, may represent primary infection after seeding during port access for band adjustment. Patients who present with port-site infection should begin taking broad-spectrum antibiotics appropriately dosed for the morbidly obese. In addition, they may require CT scanning of the abdomen and pelvis to assess for subcutaneous or intra-abdominal collections. If the band has been in place for some time, patients may need upper endoscopy to assess for band erosion. Any case of suspected port-site complication requires timely surgical consultation.

### Roux-en-Y Gastric Bypass

The Roux-en-Y gastric bypass is the most commonly performed operation for morbid obesity. It is considered to be both a restrictive and subclinical malabsorptive procedure. It reduces the amount of food that can be ingested at one meal and bypasses a segment of the small bowel, leading to incomplete digestion. Roux-en-Y has been shown to produce and maintain excess weight loss of 60% to 80% at 5 years.<sup>16-18</sup>

In this procedure, a small proximal gastric pouch is created that is capable of holding only 15 to 30 mL of ingested food and liquid. This pouch is connected to the small intestine, and a variable amount of proximal small bowel is bypassed (Figure 6). We and others have used a 150-cm Roux limb with a 100-cm biliopancreatic limb for patients with a body mass index  $> 50 \text{ kg/m}^2$  and a 100-cm Roux limb with a 50-cm biliopancreatic limb for body mass index of 35-50  $\text{kg/m}^2$ .<sup>19,20</sup>

The Roux-en-Y gastric bypass can be performed both open and laparoscopically. Although technical differences exist between the open and laparoscopic approach, the physiologic

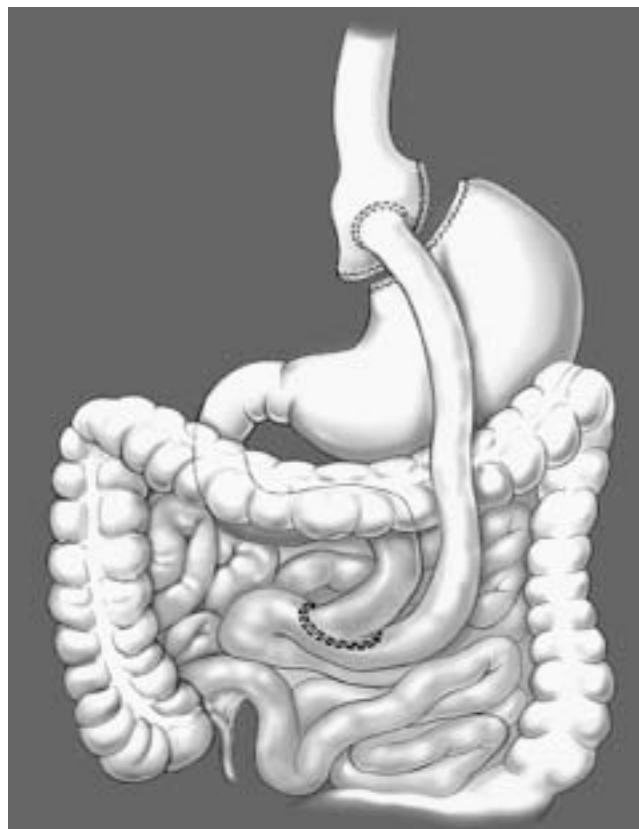


**Figure 5.** Accessing LAP-BAND port.

outcome of the surgery is the same.<sup>21</sup> The most important clinical consideration in malabsorptive procedures is that a substantial part of the small bowel is no longer in direct continuity with the digestive tract. Obstruction in this bypassed segment will provoke protean symptoms and will definitely not show any air fluid levels on plain abdominal radiographs.

Early major complications include anastomotic leak, intra-abdominal bleeding, and deep venous thrombosis or pulmonary embolism. Any patient who presents in the first weeks after a Roux-en-Y with tachycardia and fever might be harboring an anastomotic leak with associated abscess. Reported anastomotic leak rates are as high as 5.9%,<sup>22</sup> with the majority of these leaks occurring at the gastrojejunostomy.

The abdominal examination in the morbidly obese is often unrevealing, even when significant intra-abdominal pathology exists. Any suspicion for an intra-abdominal process should trigger the physician to obtain a CT scan of the abdomen and pelvis, preferably with oral and intravenous contrast. Because of the limited size of the gastric pouch, it is neither feasible nor advisable to have a patient attempt to consume the usual 1 L of oral contrast before the CT scan is performed. Our practice is to have the patient sip contrast during 3 hours and scan the patient regardless of the absolute volume consumed. Not infrequently, patients exceed the weight limit for CT scanners. If the possibility of an anastomotic leak exists and the patient cannot undergo CT scanning because of weight limitations, an upper gastrointestinal series with a water-soluble agent should be obtained. Suspicion of an anastomotic leak mandates early surgical consultation because, in addition to having significant occult pathology in their abdominal cavities, these patients also



**Figure 6.** Roux-en-Y gastric bypass.

lack the cardiopulmonary physiologic reserve of a patient of normal weight and thus can clinically deteriorate rapidly.

A rare but serious early postoperative complication is obstruction of the Roux limb that causes acute gastric dilatation. Symptoms include abdominal pain, nausea, and vomiting if the distended stomach occludes the gastrointestinal tract by compression of the Roux limb. The diagnosis is also confirmed by CT of the abdomen and can usually be treated with percutaneous decompression in interventional radiology.

Patients who have undergone Roux-en-Y can develop bleeding from the staple lines at the gastrojejunostomy (most common), the jejunojejunostomy and even along the transected edge of the gastric remnant. Patients who present early after Roux-en-Y with clinical symptoms suggestive of gastrointestinal bleeding should be resuscitated in the standard fashion. The diagnosis can be difficult to make because only bleeding from the gastrojejunostomy can be visualized with upper endoscopy. Evaluation of the other staple lines only rarely requires an operation because in most circumstances, the bleeding is self-limited and can be treated nonoperatively. Late complications of Roux-en-Y can be divided into anatomic and systemic complications (Table). Patients who undergo any type of abdominal surgery may develop adhesions and the consequences of chronic abdominal pain and bowel obstruction.

Patients who undergo a Roux-en-Y are not only at risk of developing adhesive bowel obstructions but also may develop



anastomotic strictures or internal hernias that may lead to obstruction. The incidence of stenosis at the gastrojejunostomy has been reported to be as low as 2%<sup>17</sup> and as high as 11.4%.<sup>23</sup> These patients often present with a progressive inability to tolerate solid and then liquid intake. Abdominal examination is usually unremarkable. Plain radiographs of the abdomen and CT scan will be unremarkable and should lead to consultation with a gastroenterologist or surgeon for upper endoscopy. Anastomotic strictures of the gastrojejunostomy can usually be managed endoscopically with sequential balloon dilatation, with a high degree of success.<sup>24</sup> These strictures should never be managed with blind dilatation using Maloney dilators because there is a high risk of perforation.

Internal hernias are another late complication of bypass surgery. Patients may experience small-bowel herniation through the mesenteric defect created at the distal anastomosis or through a surgically created space between the transverse colon mesentery and the mesentery of the small bowel that comprises the Roux limb. The incidence of symptomatic herniation through this space is 3% to 5% in our experience.<sup>25</sup>

Patients with internal hernias typically present with nonobstructive, intermittent, crampy, epigastric abdominal pain that often radiates to the back. Unless the obstruction has led to ischemic compromise of the bowel, the abdominal examination is usually unrevealing. The herniation is often of the “excluded” or bypassed Roux limb, and therefore there are no air fluid levels on plain radiographs. As many as 20% of patients with obstruction as a result of internal hernias will have normal CT scan results or small-bowel series.<sup>26</sup> Laboratory study results may be normal in these patients. In an article by Srikanth et al,<sup>27</sup> 5 of 6 patients with nonviable bowel because of internal hernias had a normal WBC count. The remaining patients’ scans may reveal areas of intussusception, transition points, or the classic “swirl sign” created by twisting of the bowel mesentery. Any patient with unexplained abdominal pain, regardless of laboratory or radiologic findings, should be considered for surgical exploration.

In addition to the anatomic consequences of bypass surgery, there is also a host of metabolic complications that can arise. After undergoing Roux-en-Y, many patients will develop

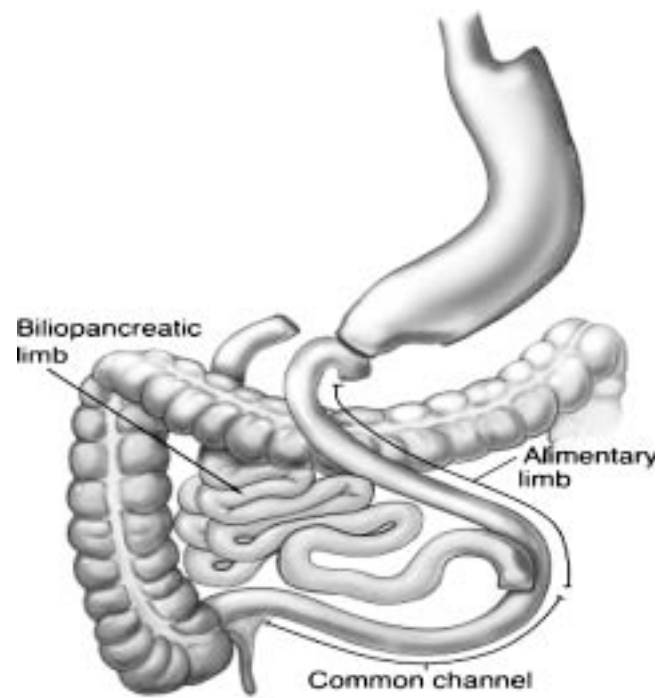


Figure 7. Biliopancreatic diversion with duodenal switch.

nutritional deficiencies. Deficiencies in iron, vitamin B12, vitamin D, and calcium are common.<sup>28</sup> Most patients receive vitamin supplementation and have markers of nutritional status monitored periodically. Of particular concern is the fact that most patients manifest evidence of secondary hyperparathyroidism after Roux-en-Y. Numerous studies have demonstrated increased bone turnover and decreased bone density.<sup>29,30</sup> The implications of bone density loss have yet to be determined but may result in significant morbidity for patients, particularly postmenopausal women.

Biliopancreatic Diversion

The biliopancreatic diversion is a complicated malabsorptive and restrictive weight loss procedure. It involves decreasing the size of the stomach and an extensive bypass of the duodenum and jejunum (Figure 7). A common variation of this technique

Table. Late complications.

Complication	Presentation	Diagnosis	Management
<b>Anatomic</b>			
Stricture/stenosis	Inability to tolerate oral intake, dysphagia	UGI series, upper endoscopy	Endoscopic dilatation
Marginal ulcer	Epigastric abdominal pain, dyspepsia	Upper endoscopy	Acid suppression therapy
Internal hernia	Intermittent, crampy abdominal pain	CT scan, UGI series	Surgical consultation
Reflux	Dyspepsia, new-onset asthma/worsening preexisting pulmonary disease	Upper endoscopy, cholescintigraphy	Acid suppression therapy, surgical consultation
<b>Systemic</b>			
Nutritional	Anemia, neuropathy, fractures, hypercalcemia	CBC, iron studies, PTH level, vitamin D, vitamin A, B12 levels, micronutrient levels	Surgical consultation, nutritional consultation

UGI, Upper gastrointestinal; CT, computed tomography, PTH, parathyroid hormone.

uses the “duodenal switch,” which bypasses the jejunum but leaves a larger portion of the stomach intact, including the pylorus. The biliopancreatic diversion with duodenal switch allows for a large amount of weight loss while preventing the development of dumping syndrome. The operation itself is technically complex and has only recently been performed laparoscopically.<sup>31</sup>

Patients undergoing the biliopancreatic diversion with or without duodenal switch are at risk for developing the same types of complications described for the Roux-en-Y. However, in exchange for a larger amount of excess weight loss, there is a higher rate of metabolic abnormalities. In addition to deficiencies in iron, vitamin B12, vitamin D, and calcium, patients undergoing biliopancreatic diversion experience fat-soluble-vitamin deficiencies.<sup>32</sup> Patients may also develop deficiencies in selenium and zinc. Rarely, patients develop hepatic dysfunction after biliopancreatic diversion. One recent study revealed that it may occur in 2.1% of patients undergoing biliopancreatic diversion.<sup>33</sup> This dysfunction may manifest itself as subclinical liver enzyme level elevation, jaundice, or hepatic failure. There has been 1 reported case of a patient successfully undergoing liver transplantation for hepatic failure after biliopancreatic diversion.<sup>34</sup>

## Conclusion

Morbid obesity is now considered an epidemic in this country. The number of individuals who submit to weight loss surgery is increasing every year. As these numbers increase, so too will the number of ED visits for postoperative complications. Clinicians working in the ED should have a basic understanding of the various procedures performed for weight loss, as well as management of common complications.

*Supervising editor:* J. Stephan Stapczynski, MD

*Funding and support:* The authors report this study did not receive any outside funding or support.

*Publication dates:* Received for publication March 4, 2005. Revision received June 23, 2005. Accepted for publication June 29, 2005. Available online August 15, 2005.

*Address for reprints:* Alfons Pomp, MD, Department of Surgery, New York-Presbyterian Hospital, 525 East 68th Street, New York, NY 10021; 212-746-5294, fax 212-746-5236; E-mail alp2014@med.cornell.edu.

## REFERENCES

- Pastor PN, Makuc DM, Reuben C, et al. *Chartbook on Trends in the Health of Americans: Health, United States, 2002*. Hyattsville, MD: National Center for Health Statistics; 2002.
- Flegal KM, Carroll MD, Ogden CL. Prevalence and trends in obesity among US adults, 1999-2000. *JAMA*. 2002;288:1723-1727.
- Wittgrove AC, Clark GW, Tremblay LJ. Laparoscopic gastric bypass, Roux-en-Y: preliminary report of five cases. *Obes Surg*. 1994;4:353-357.
- Schirmer B, Watts SH. Laparoscopic bariatric surgery. *Surg Endosc*. 2003;17:1875-1878.
- Olbers T, Lonroth H, Dalenback J, et al. Laparoscopic vertical banded gastroplasty: an effective long-term therapy for morbidly obese patients? *Obes Surg*. 2001;11:726-730.
- Balsiger BM, Poggio JL, Mai J, et al. Ten and more years after vertical banded gastroplasty as primary operation for morbid obesity. *J Gastrointest Surg*. 2000;4:598-605.
- del Amo DA, Diez MM, Guedea ME, et al. Vertical banded gastroplasty: is it a durable operation for morbid obesity? *Obes Surg*. 2004;14:536-538.
- Biertho L, Steffen R, Ricklin T, et al. Laparoscopic gastric bypass versus laparoscopic adjustable gastric banding: a comparative study of 1,200 cases. *J Am Coll Surg*. 2003;197:536-544.
- Patel SM, Shapiro K, Abdo Z, et al. Obstructive symptoms associated with the Lap-Band in the first 24 hours. *Surg Endosc*. 2004;18:51-55.
- Shen R, Ren CJ. Removal of peri-gastric fat prevents acute obstruction after Lap-Band surgery. *Obes Surg*. 2004;14:224-229.
- Wiesner W, Weber M, Hauser RS, et al. Anterior versus posterior slippage: two different types of eccentric pouch dilatation in patients with adjustable laparoscopic gastric banding. *Dig Surg*. 2001;18:182-186.
- Suter M, Giusti V, Heraief E, et al. Band erosion after laparoscopic gastric banding: occurrence and results after conversion to Roux-en-Y gastric bypass. *Obes Surg*. 2004;14:381-386.
- Abu-Abeid S, Szold A. Laparoscopic management of Lap-Band erosion. *Obes Surg*. 2001;11:87-89.
- Susmallian S, Ezri T, Elis M, et al. Access-port complications after laparoscopic gastric banding. *Obes Surg*. 2003;13:128-131.
- Yoffe B, Sapojnikov S, Lebedev V, et al. Disconnection of port after laparoscopic gastric banding: causes and solution. *Obes Surg*. 2003;13:784-787.
- Wittgrove AC, Clark GW. Laparoscopic gastric bypass, Roux-en-Y: 500 patients: technique and results, with 3-60 month follow-up. *Obes Surg*. 2000;10:233-239.
- Schauer PR, Ikramuddin S, Gourash W, et al. Outcomes after laparoscopic Roux-en-Y gastric bypass for morbid obesity. *Ann Surg*. 2000;232:515-529.
- MacLean LD, Rhode BM, Nohr CW. Late outcome of isolated gastric bypass. *Ann Surg*. 2000;231:524-528.
- MacLean LD, Rhode BM, Nohr CW. Long- or short-limb gastric bypass? *J Gastrointest Surg*. 2001;5:525-530.
- Inabnet WB, Quinn T, Gagner M, et al. Laparoscopic Roux-en-Y gastric bypass in patients with BMI <50: a prospective randomized trial comparing short and long limb lengths. *Obes Surg*. 2005;15:51-57.
- Nguyen NT, Goldman C, Rosenquist CJ, et al. Laparoscopic versus open gastric bypass: a randomized study of outcomes, quality of life, and costs. *Ann Surg*. 2001;234:279-289.
- Lujan JA, Frutos MD, Hernandez Q, et al. Laparoscopic versus open gastric bypass in the treatment of morbid obesity: a randomized prospective study. *Ann Surg*. 2004;239:433-437.
- Podnos YD, Jimenez JC, Wilson SE, et al. Complications after laparoscopic gastric bypass: a review of 3464 cases. *Arch Surg*. 2003;138:957-961.
- Nguyen NT, Stevens CM, Wolfe BM. Incidence and outcome of anastomotic stricture after laparoscopic gastric bypass. *J Gastrointest Surg*. 2003;7:997-1003.
- Comeau E, Gagner M, Inabnet WB, et al. Symptomatic internal hernias after laparoscopic bariatric surgery. *Surg Endosc*. 2005;19:34-39.
- Higa KD, Ho T, Boone KB. Internal hernias after laparoscopic Roux-en-Y gastric bypass: incidence, treatment and prevention. *Obes Surg*. 2003;13:350-354.
- Srikanth MS, Keskey T, Fox SR, et al. Computed tomography patterns in small bowel obstruction after open distal gastric bypass. *Obes Surg*. 2004;14:811-822.

28. Alvarez-Leite JJ. Nutrient deficiencies secondary to bariatric surgery. *Curr Opin Clin Nutr Metab Care*. 2004;7:569-575.
29. Coates PS, Fernstrom JD, Fernstrom MH, et al. Gastric bypass surgery for morbid obesity leads to an increase in bone turnover and a decrease in bone mass. *J Clin Endocrinol Metab*. 2004;89:1061-1065.
30. Goode LR, Brolin RE, Chowdhury HA, et al. Bone and gastric bypass surgery: effects of dietary calcium and vitamin D. *Obes Res*. 2004;12:40-47.
31. Ren CJ, Patterson E, Gagner M. Early results of laparoscopic biliopancreatic diversion with duodenal switch: a case series of 40 consecutive patients. *Obes Surg*. 2000;10:514-523.
32. Slater GH, Ren CJ, Siegel N, et al. Serum fat-soluble vitamin deficiency and abnormal calcium metabolism after malabsorptive bariatric surgery. *J Gastrointest Surg*. 2004;8:48-55.
33. Baltasar A, Serra C, Perez N, et al. Clinical hepatic impairment after the duodenal switch. *Obes Surg*. 2004;14:77-83.
34. Castillo J, Fabrega E, Escalante CF, et al. Liver transplantation in a case of steatohepatitis and subacute hepatic failure after biliopancreatic diversion for morbid obesity. *Obes Surg*. 2001;11:640-642.

## IMAGES IN EMERGENCY MEDICINE

(continued from p. 134)

### DIAGNOSIS:

*Orbital cellulites with subperiosteal abscess.* Orbital cellulitis is an acute infection commonly caused by *Streptococcus pneumoniae*, other streptococci, *Staphylococcus aureus*, *M catarrhalis* and *Haemophilus influenza* (rarely due to Hib vaccine). Pathogens enter the orbit by direct extension (paranasal sinuses) or by hematogenous spread. Clinical findings include fever, periorbital swelling, and redness. Limitation of ocular movement and proptosis may be subtle and differentiate this from “periorbital” cellulitis. The importance of orbital CT cannot be underestimated to rule out the possibility of abscess formation. All cases of orbital cellulitis require admission for intravenous antibiotics and management of possible complications, including subperiosteal abscess, meningitis, cavernous sinus thrombosis, and intracranial abscess formation.

Key for Figure 3:

- A. Proptosis
- B. Medial Rectus
- C. Subperiosteal Abscess
- D. Lamina Papyracea
- E. Ethmoid Sinus